

# Recurrent Granuloma in the Nose: A Diagnostic Challenge

Laura Andrea Sinuco<sup>1</sup>, Ángel Omar Jaimes<sup>2,\*</sup>, Claudia González<sup>3</sup> and Ligia Méndez Gaviria<sup>4</sup>

<sup>1</sup>Dermatology Resident, Sanitas University Foundation, Federico Lleras Acosta Dermatology Center University Hospital, <sup>2</sup>Specialist in oncological dermatology, Central Military Hospital, Federico Lleras Acosta Dermatological Center University Hospital, <sup>3</sup>Specialist in radiology and diagnostic images. Rosario University and <sup>4</sup>Specialist in dermatology, Central Military Hospital

**Abstract:** Recurrent granulomatous lesions in the facial region are difficult to diagnose. High-resolution dermatological ultrasound is an important key to the proper diagnostic orientation in this kind of lesions, by allowing the identification of its etiological factor and establishing the precise anatomical relationships for its proper intervention. We present the case of a young patient with a recurrent granuloma in the nasal ala whose correct diagnosis was made with high-resolution dermatological ultrasound, facilitating the successful treatment.

**Keywords:** Granuloma, Tensor Threads, High Resolution Ultrasound.

## INTRODUCTION

Recurrent granulomatous lesions in the facial region are difficult to diagnose for several reasons: biopsies may not be conclusive, the recall bias in patients when mentioning their medical history, or what the treating physician considers relevant in the questioning. The case of a young patient with a recurrent lesion in the left nasal alar lobe is presented, despite being subjected to several procedures without achieving a diagnosis or cure, and how, through multidisciplinary work, it was possible to reach the origin of the recurring lesion.

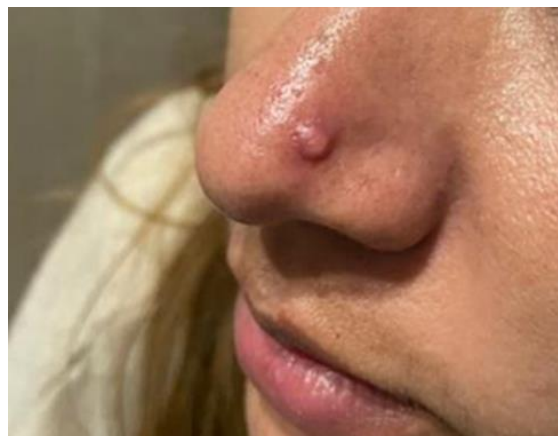## CLINICAL CASE

A 31-year-old female patient who consulted for a mass in the left nasal alar lobe after two years of evolution reported having had a piercing in that area eight years ago, with no other associated medical history (**Figure 1A**). Extra-institutionally, they performed cauterization of the lesion with its reappearance a week later, for which she consulted her health care centre, where they indicated an ultrasound scan that reported findings suggestive of an epidermal cyst. Plastic Surgery resected the lesion, whose pathology reported an inflammatory reaction to a foreign body. Two months later, the lesion reappeared, and she decided to consult dermatology where they took a biopsy. This pathology reported: a severe inflammatory component in the dermis constituted by lymphocytes, histiocytes, some neutrophils, and foreign body-type multinucleated giant cells.

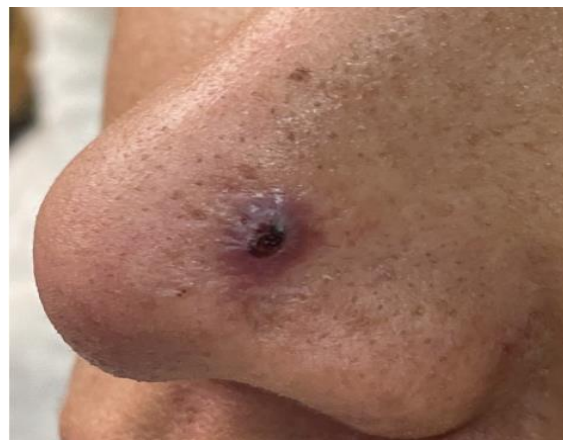One month later, the lesion reappeared in the same location and was managed with 100% intralesional triamcinolone 0.5 ml on two occasions, without improvement and now with purulent discharge. On admission to our institution, the physical examination revealed an erythematous-violaceous papule on the left nasal alar lobe with a bloody crust on its surface, located over the scarred area, with scant purulent discharge (**Figure 1B**).

Conventional soft tissue ultrasound with a linear transducer reported a probable foreign body granuloma

referred to as a suture. Questioning the patient once again, she mentioned that two years before the onset of the symptoms, she underwent rhino moderation with CARA® PDO Thread (polydioxanone) tension in a beauty clinic by non-dermatologist personnel, and with this information, we decided to request a high-resolution ultrasound to rule out a fistulous tract. Ultrasound was performed with a linear 18 MHz transducer and showed a hypo echoic solid nodule with poorly defined, irregular borders measuring 6.6 × 6 × 6.7 mm, with a foreign body



**Figure 1A:** It is the initial clinical image of the patient with a nodule on the nasal dorsum with intermittent purulent discharge after two years of evolution.

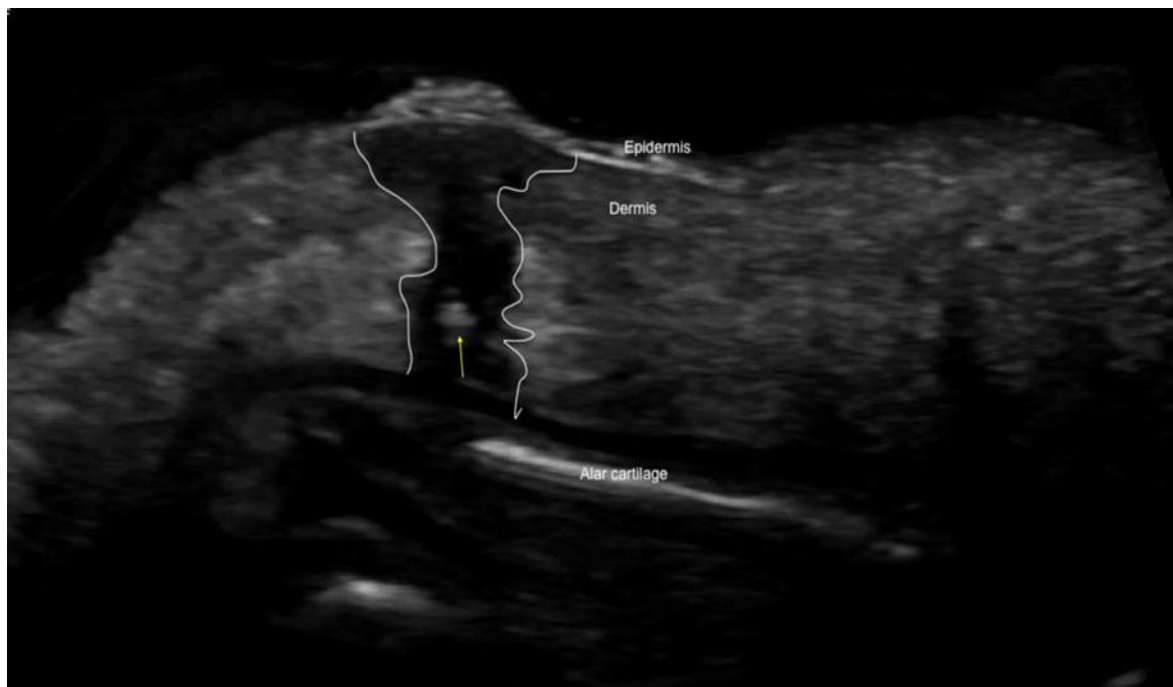

**Figure 1B:** It is the reappearance of the lesion after the first surgical intervention in the same area and the persistence of serohematic secretion.

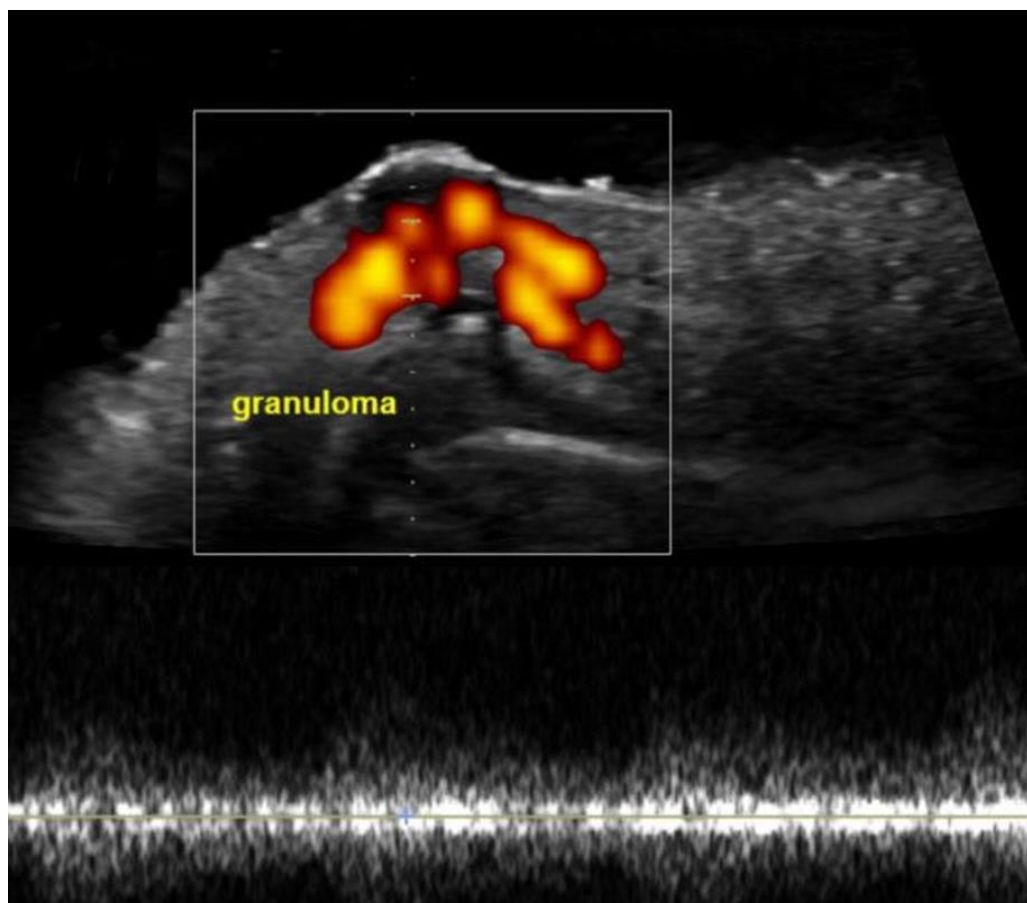
\*Address corresponding to this author at the Specialist in oncological dermatology, Central Military Hospital, Federico Lleras Acosta Dermatological Center University Hospital; Email: claud\_gonzalezdiaz@yahoo.com

inside, linear hyperechogenic, compatible with suture thread. Duplex Doppler analysis showed intraregional vessels with peak systolic velocity ranging from 16 cm/s.

Image matching with foreign body granuloma (suture) and possible changes of telangiectatic granuloma (**Figure 2**).



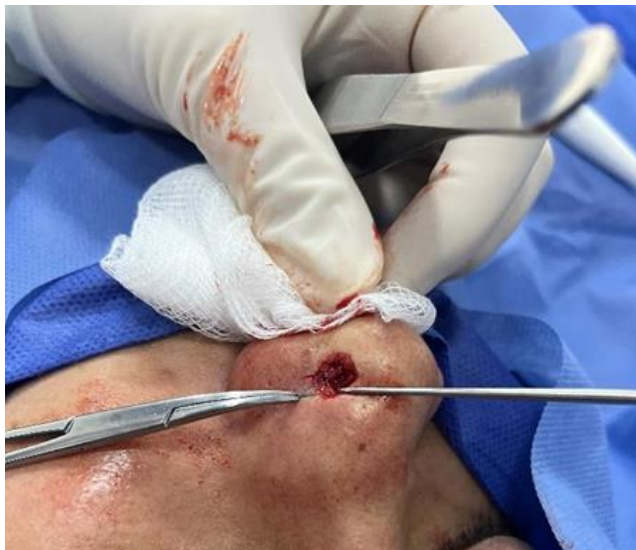**Figure 2A:** High resolutions ultrasound, a grey-scale longitudinal view of the dorsal nasal area, shows between the line a hypoechoic , longitudinal, , irregular lesion that extends from the epidermis to the alar cartilage, inside the lesion the yellow arrows show a linear hyperechoic image corresponding to a foreign body.(tensor thread)



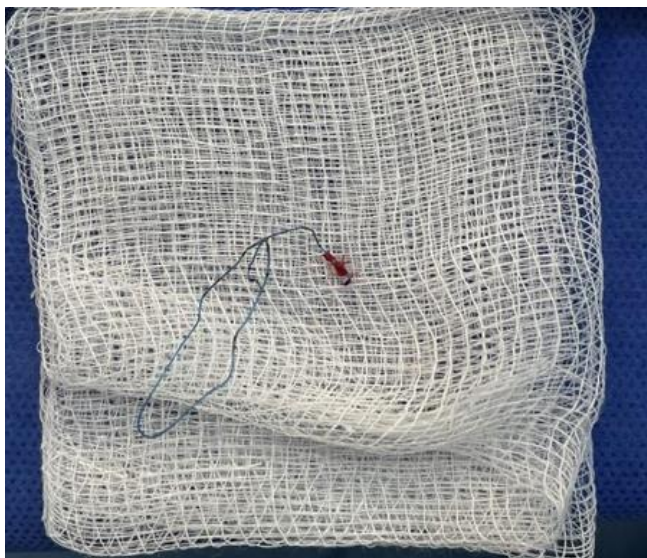**Figure 2B:** Power Doppler ultrasound shows an important increase in vascularisation inside the lesion, the spectral curve corresponds to an arterial low-resistant vessel.

She was taken to the operating room by the plastic surgery service, finding the thread reported in the high-resolution ultrasound (**Figure 3A** and **Figure 3B**).

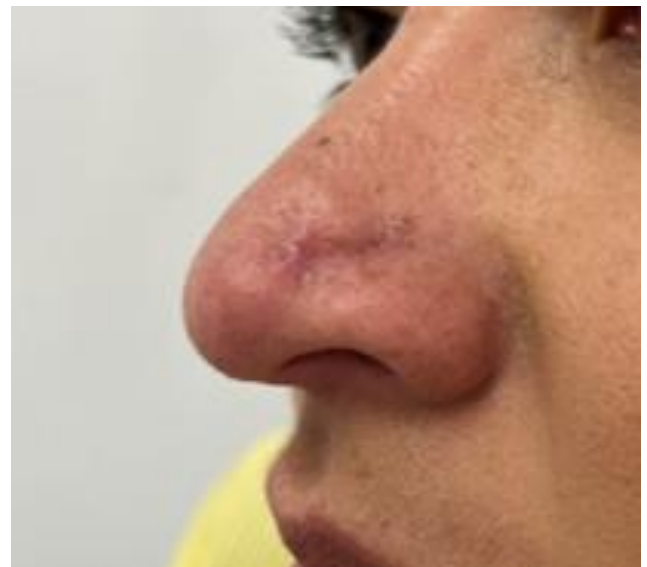The patient attended the follow-up two months later, finding a scar with no signs of recurrence of the resected lesion (**Figure 3C**). Pathology of the lesion reported loss of adnexal structures and an intense infiltrate of an acute suppurative nature and more peripherally a chronic granulomatous one with gigantocellular reaction of the foreign body type, as well as some fibrosis and collagen homogenization with verticalization of vessels that configure a repair process. No malignancy or other types of findings were documented.



**Figure 3A:** Clinical images; during the surgical procedure where the tensors thread is located.



**Figure 3B:** Specimen resected with the tensor thread.



**Figure 3C:** Clinical image of the patient two months after the successful surgical procedure

## DISCUSSION

The performance of minimally invasive procedures has been increasing, as they allow quick recovery and minimal scarring. Among these is the lifting with threads or Thread-lifting with sutures, whether absorbable or non-absorbable, which only require an incision for their application (1,2).

Barbed sutures have been used since 1964 for knotless wound closure, but in Germany in 1989, Sulamanidze used non-absorbable barbed polypropylene sutures known as APTOS (for their “anti-ptosis” effect) to perform facelift procedures. (3,4). Due to their easy application and fast recovery, they have gained popularity as a substitute for cosmetic procedures such as conventional rhinoplasty (4,5).

Currently, the sutures used for thread-lifting are monofilament threads with bidirectional barbs that make them self-retaining in the tissue (6). The suture material can be absorbable (polydioxanone, polycaprolactone, and polylactic acid, which degrade in 4 to 6 months) or non-absorbable such as polypropylene, which is ideal if a long-term effect is sought (1,3,7). The barbs or cones allow their advancement through the skin and avoid recoil in the tissue, requiring their manual positioning when pulling the skin before cutting the tip of the thread (8). L-poly-lactic acid knots can be added to these barbs, which are absorbed and generate an inflammatory reaction to a foreign body, allowing the formation of a fibrous capsule that adheres to the suture to the surrounding tissue, in addition to stimulating collagen production (6).

Polydioxanone is a synthetic monofilament polymer used for the manufacture of absorbable sutures since 1981, characterized by its biocompatibility and absorption time of approximately 6 months (longer than Vicryl®) (2,9). According to a study by Jang et al. carried out in mice, the myofibroblasts surround the suture allowing a contraction of the fibrous tissue from 4

weeks after its application to the skin, forming a fibrous capsule that maintains the traction of the tissue (9,10). In addition, the presence of inflammatory tissue, multinucleated giant cells, and elastic, and collagen fibers has been described up to six months after placing this material (2).

According to a study conducted by Jin et al., many absorbable sutures have been found intact in the nose of patients even years after their placement. This is attributed to the small amount of soft tissue in this area of the body and the simultaneous application of fillers that block the response that hydrolyzes the suture (11). A study was carried out in China between 2014 and 2020, which reported complications in 190 patients treated with these threads. They reported dimpling of the skin (40.5%), contour irregularities (16.8%), visible sutures (16.3%), suture extrusion (5.3%), infection (8.9%), edema (4.7%), et cetera (5). The formation of granulomas has also been described as complications secondary to the use of these sutures, and although these chronic inflammatory reactions are not the most frequent, they are attributed to repetitive trauma and micro-movement between the barbed sutures and the capsule that surrounds them (1,3).

High-resolution ultrasound has proven to be the diagnostic method of choice for the characterization of multiple dermatological lesions, inflammatory, tumoral, vascular, and complications from cosmetic procedures, among others (12–15). The study must be carried out following the guidelines developed for its practice and allows, due to the greater spatial resolution in megapixels of transducers greater than 15 MHz, to make an adequate identification of sub centimeter elements, as in the case of our patient, corresponding to a suture inside the nodule that is the key to its diagnosis (16). These types of findings with linear transducers of lower resolution are not detectable (17).

Two more factors to highlight are the importance of using a copious amount of gel, especially in areas such as the nose, since if this acoustic window is not used, the lesions can be compressed by the transducer itself and not be visible or limit its characterization.; Lastly, the study must be performed by a doctor with training in imaging and dermatological pathology (14). Carrying out dermatological ultrasound studies in this way allows obtaining the maximum amount of information possible, such as suture elements inside the lesion, the relationship with the alar cartilage, and the other anatomical precisions observed in this case. Regarding the vascularized component appreciated by the Doppler evaluation, in the pathology, the presence of angiogenesis with verticalization of vessels in the periphery of the lesion was confirmed, and this confirms the importance of color Doppler Duplex exploration of all dermatological lesions, allowing a more detailed characterization analysis of the lesions, differentiating between solid, cystic, vascular origin lesions and inflammatory pathologies, establishing disease activity and monitoring evolution and treatment (15).

On the other hand, the use of antibiotics and non-steroidal anti-inflammatory drugs has been described as part of the treatment for chronic inflammatory reactions secondary to thread-lifting; however, surgical excision is the most effective method to eliminate the symptoms (1, 18).

## CONCLUSION

The case of a young patient with a recurrent granuloma in the nasal ala secondary to rhino modelling with tensor threads is presented. The tensor threads in the tissue initiate an inflammatory response which, associated with the trauma to this area (nose) and the multiple attempts to remove the lesion, could perpetuate the inflammation and angiogenesis. High-resolution dermatological ultrasound was key to the proper diagnostic orientation of the lesion, by allowing the identification of its etiological factor (tensor thread) and establishing the precise anatomical relationships for proper surgical planning, achieving a successful procedure. Likewise, emphasis is placed on the importance of a detailed anamnesis to establish the cause of the lesion, since many times the memory of the patients does not provide important data or they consider that they are not relevant, hindering or delaying the proper diagnosis.

## REFERENCES

- [1] Ahn SK, Choi HJ. Complication After PDO Threads Lift: Journal of Craniofacial Surgery. 2019;30(5):e467-9. <https://doi.org/10.1097/scs.0000000000005644>
- [2] Hernández Machín B. Hilos tensores en Dermatología. Piel. abril de 2015;30(4):261-6. <https://doi.org/10.1016/j.piel.2014.11.006>
- [3] Wu W. Barbed sutures in facial rejuvenation. Aesthetic Surgery Journal. diciembre de 2004;24(6):582-7. <https://doi.org/10.1016/j.asj.2004.09.007>
- [4] Sulamanidze M, Sulamanidze G, Vozdvizhensky I, Sulamanidze C. Avoiding Complications With Aptos Sutures. Aesthetic Surgery Journal. 1 de noviembre de 2011;31(8):863-73. <https://doi.org/10.1177/1090820x11422700>
- [5] Li YL, Li ZH, Chen XY, Xing WS, Hu JT. Facial Thread Lifting Complications in China: Analysis and Treatment. Plastic and Reconstructive Surgery - Global Open. 17 de septiembre de 2021;9(9):e3820. <https://doi.org/10.1097/gox.0000000000003820>
- [6] Halepas S, Chen XJ, Ferneini EM. Thread-Lift Sutures: Anatomy, Technique, and Review of Current Literature. Journal of Oral and Maxillofacial Surgery. mayo de 2020;78(5):813-20. <https://doi.org/10.1016/j.joms.2019.11.011>

- [7] Rezaee Khiabanloo S, Nabie R, Aalipour E. Outcomes in thread lift for face, neck, and nose; A prospective chart review study with APTOS. *J Cosmet Dermatol*. noviembre de 2020;19(11):2867-76. <https://doi.org/10.1111/jocd.13397>
- [8] Sarigul Guduk S, Karaca N. Safety and complications of absorbable threads made of poly-L-lactic acid and poly lactide/glycolide: Experience with 148 consecutive patients. *J Cosmet Dermatol*. diciembre de 2018;17(6):1189-93. <https://doi.org/10.1111/jocd.12519>
- [9] Suh DH, Jang HW, Lee SJ, Lee WS, Ryu HJ. Outcomes of Polydioxanone Knotless Thread Lifting for Facial Rejuvenation. *Dermatologic Surgery*. junio de 2015;41(6):720-5. <https://doi.org/10.1097/dss.0000000000000368>
- [10] Jook Jang H, Lee WS, Hwang K, Park JH, Kim DJ. Effect of Cog Threads under Rat Skin. *Dermatologic Surgery*. diciembre de 2005;31(12):1639-44. <https://doi.org/10.2310/6350.2005.31301>
- [11] Jin HR, Kim SJ. Presentation Patterns and Surgical Management of the Complications of Thread Rhinoplasty. *Clin Exp Otorhinolaryngol* [Internet]. 8 de abril de 2022 [citado 20 de agosto de 2022]; Disponible en. <https://doi.org/10.21053/ceo.2022.00101>
- [12] González CP. Ultrasonido de alta resolución en enfermedades benignas de la piel. *Rev Asoc Colomb Dermatol Cir Dematol*. 7 de febrero de 2019;26(4):230-9. <https://doi.org/10.29176/2590843x.124>
- [13] González CP. Characterization of Dermatological Lesions by Ultrasound. *Rev Colomb Radiol*. 2014;25(3):4006-14. <https://doi.org/10.53903/issn.0121-2095>
- [14] Díaz CPG. High resolution ultrasound of soft tissues for characterization of fillers and its complications. :5.
- [15] Wortsman X. Common Applications of Dermatologic Sonography. *Journal of Ultrasound in Medicine*. enero de 2012;31(1):97-111. <https://doi.org/10.7863/jum.2012.31.1.97>
- [16] Wortsman X, Alfageme F, Roustan G, Arias-Santiago S, Martorell A, Catalano O, et al. Guidelines for Performing Dermatologic Ultrasound Examinations by the DERMUS Group. *Journal of Ultrasound in Medicine*. marzo de 2016;35(3):577-80. <https://doi.org/10.7863/ultra.15.06046>
- [17] González CP. Ultrasonido de alta resolución en enfermedades benignas de la piel. *rev asoc colomb dermatol cir dematol*. 7 de febrero de 2019;26(4):230-9. <https://doi.org/10.29176/2590843x.124>
- [18] Rachel JD, Lack EB, Larson B. Incidence of Complications and Early Recurrence in 29 Patients After Facial Rejuvenation with Barbed Suture Lifting. *Dermatologic Surgery*. marzo de 2010;36(3):348-54. <https://doi.org/10.1111/j.1524-4725.2009.01442.x>

---

Received on 20-07-2023

Accepted on 26-08-2023

Published on 15-09-2023

© 2023 Jaimes *et al.*; Green Publishers

This is an open access article licensed under the terms of the Creative Commons Attribution Non-Commercial License(<http://creativecommons.org/licenses/by-nc/3.0/>), which permits unrestricted, non-commercial use, distribution and reproduction in any medium, provided the work is properly cited.