

# Popliteal Pterygium Syndrome (Facio-Genito-Popliteal Syndrome)

N. Mariappan\* and Sanket Shetty

Vydehi Institute of Medical Sciences and Research Center, Bengaluru, India

**Abstract: Background:** *IRF6*-related disorders span a spectrum from isolated cleft lip and palate and Van der Woude syndrome (VWS) at the mild end to popliteal pterygium syndrome (PPS) at the more severe end. Popliteal pterygia are found in popliteal pterygium syndrome, multiple pterygium syndrome and Arthrogryposis. The popliteal pterygium syndrome is a rare congenital condition, in which the patient has facial, genitourinary and skeletal anomalies along with popliteal pterygium. Autosomal dominant popliteal pterygium syndrome (AD-PPS) is a rare genetic malformation disorder characterized by cleft lip, with or without cleft palate, contractures of the lower extremities, abnormal external genitalia, syndactyly of fingers and/or toes, and a pyramidal skin fold over the hallux nail. *AD-PPS is associated with mutations in the IRF6 gene (1q32.2-q32.3), involved in the formation of connective and epithelial tissues.* Almost all affected patients harbor mutations in this gene. The word 'pterygium' is derived from the Greek word *pterygion*, which means wing. Pathologically it denotes a wing-like abnormal band of tissue. The most obvious characteristics of this syndrome are popliteal pterygium and a triangular crease of skin over the hallux. The orofacial findings include cleft lip, cleft palate, lower lip pits, a few missing teeth, and severely decayed teeth. The dental problems are overshadowed by the major syndromic manifestations. These patients have special dental needs and early preventive dental care and appropriate dental treatment at the optimal time is important. Diagnosis of pterygium syndrome is based on the clinical findings and confirmed by molecular genetic testing. AD-PPS is highly associated with missense mutations that alter residues that are predicted to interact directly with DNA in exons 3 and 4 of *IRF6*. **Conclusion:** An understanding of the molecular genetic basis of this syndrome is essential for prenatal diagnosis and also for genetic counseling of the parents.

**Keywords:** Popliteal pterygium syndrome, Escobar syndrome, Magnetic resonance imaging, Congenital contractures, Genetic counseling.

## 1. INTRODUCTION

Trelat first recorded a case of popliteal pterygium syndrome in 1869 [1]. It was named as such by Gorlin [2]. Rintala and Lahti suggested the term "facio-genito-popliteal syndrome" [3]. Various hypothesis of pathogenesis of this condition have included:

- ✦ A primary microvascular abnormality with associated edema leading to disturbance of epithelial tissues, resulting in adhesion formation,
- ✦ Excessive epithelial growth leading to fusion and secondary mesenchymal involvement,
- ✦ A primary collagen defect and
- ✦ Loss of programmed cell death.

Popliteal pterygium syndrome is a rare autosomal dominant disorder in a 1:1 male: female ratio, with an incidence of 1/300,000. Fewer than 200 cases have been described in literature to date. The condition has been transmitted from an affected parent to one or more children [4,5]. There have been affected siblings with normal parents as in Escobar syndrome [6]. Strong evidence suggests autosomal dominant inheritance

with variable expressivity and incomplete penetrance [7]. The popliteal pterygium syndrome maps to the van der woude region at1q32 in some patients [8]. Hunter and Froster-Iskenius have given an excellent analysis of this condition [9]. The neck pterygium or webbed neck may be associated with trisomy 21, 13 and Turner's syndrome. Arthrogryposis Multiplex Congenita (AMC) is defined as congenital, non-progressive contractures in more than two joints and in multiple body areas. Distal arthrogryposis (DA) is classified as

- Primary musculoskeletal involvement: Amyoplasia or "Classic arthrogryposis", Camptodactyly syndromes, PPS, DA type 1 and symphalangism syndromes.
- Musculoskeletal involvement along with other system anomalies: Camptodactyly syndromes, myotonic dystrophy, congenital myopathies, Marfan syndrome.
- Musculoskeletal involvement along with CNS dysfunction and / or mental retardation: Lethal MPS, cerebro-oculo-facio-skeletal syndrome [10]. Arthrogryposis multiplex congenita is usually symmetrical and it involves the extremities and it significantly limits the joint movement due to combined amyotrophy and it causes the loss of skin creases.

\*Address correspondence to this author at the Vydehi Institute of Medical Sciences and Research Centre, Bengaluru, India; Tel: 091-9901043568; E-mail: drn\_m@hotmail.com

**Table 1: Phenotype-Gene Relationship of Popliteal Pterygium Syndrome**

Location	Phenotype	Phenotype MIM Number	Inheritance	Phenotype Mapping Key	Gene/Locus	Gene/Locus Number
1q32.2	Popliteal pterygium syndrome	1195500	AD	3	IRF6	607199

### 1.1. Genetic Basis of Popliteal Pterygium Syndrome

The diagnosis of PPS is based on a *classical triad* (Craniofacial, Genitourinary and, extremity deformities including the popliteal pterygium) and genetic malformations. Phenotype-Gene relationship located in 1q32.2 chromosome (Table 1). The presence of at least three of five abnormalities is considered diagnostic of this syndrome - Cleft lip or palate, popliteal pterygium, Para-median lower lip sinuses Genito-urinary anomalies and Extremity anomalies.

The popliteal pterygium syndrome is caused by a heterozygous mutation in the gene encoding interferon regulatory factor-6 (IRF6; 607199) on the chromosome 1q32. Kondo *et al.* [11] by direct sequence analysis of genes and presumptive transcripts in the critical region for PPS and Van der Woude syndrome (VWS1; 119300) identified by linkage analysis on 1q32 [11]. VWS is the most frequent form of syndromic orofacial clefting, accounting for up to 2% of all cleft cases, and is one of the rare monogenic syndromes where clefts of both the primary and secondary palate are seen within the same family. They identified mutations in the interferon regulatory factor 6 gene that shares most of the features with popliteal pterygium syndrome. Van der Woude syndrome and popliteal pterygium syndrome are allelic and have phenotypic overlap as both syndromes are due to genetic mutations affecting interferon regulatory factor 6 gene. Lees *et al.* [12] obtained a multipoint LOD (Log of the Odds score method) score of 2.7 with no evidence of recombination; by linkage analyze study using the markers D1S205, D1491 and D1S3753 [12]. The genetics of clinical variability in IRF6-related disorders is still under research. Genotype-

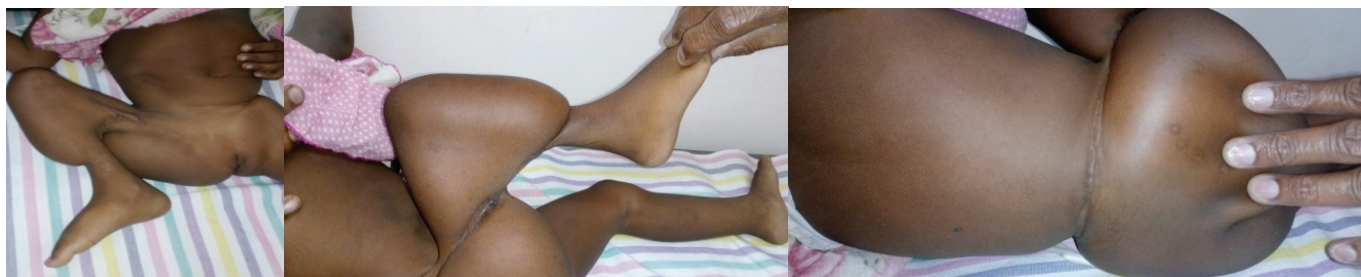
phenotype correlations revealed that mutations causing popliteal pterygium syndrome are mainly restricted in the highly conserved DNA-binding domain (exons 3 and 4), whereas those causing VWS are observed in both in- and out- of the DNA-binding domain, mostly in exons 3, 4, 7, and 9 [13]. Recent genetic association studies suggested that

- Mutations in FOXE1, TGFB3, and TFAP2A genes could influence condition's severity [14].
- Non-genetic modifiers had also been suggested in the genesis of the condition [15].

### 2. CLINICAL CASE PRESENTATION

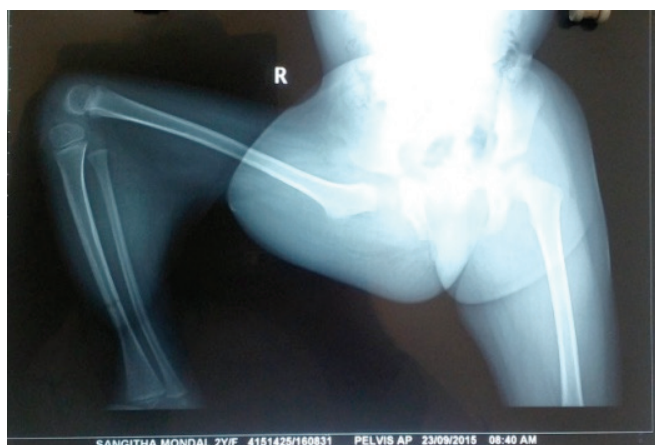A one year and six months old female child presented to plastic surgery out-patient department with complaints related to popliteal pterygium syndrome. She is the eldest child born of first-degree consanguineous marriage parents. She was seen and diagnosed in a Kolkata hospital at the age of 4 months and surgery was done for constriction rings of the right leg. On examination the child has severe flexion contracture of the right lower limb at the hip and knee joint. The scar of previous surgery for the constriction rings of the right lower leg is evident (Figure 1).

Subcutaneous constriction rings correction scars are seen in the lower part of the right leg. Plain X-ray of the extremities are normal with no deformities of the joints (Figure 2). MRI showed the popliteal artery is seen coursing away from the skin fold with normal blood flow is seen (Figure: 3). The patient was sent for evaluation by Orthopedic surgeon. The patient was planned for a complex surgical procedure.



**Figure 1:** First child born of consanguineous parents with popliteal pterygium syndrome. The scars of previous surgery are present.





**Figure 2:** Plain X-ray of the pelvis along with the affected right lower limb shows normal bone development.

### 3. CLINICAL MANIFESTATIONS OF PPS

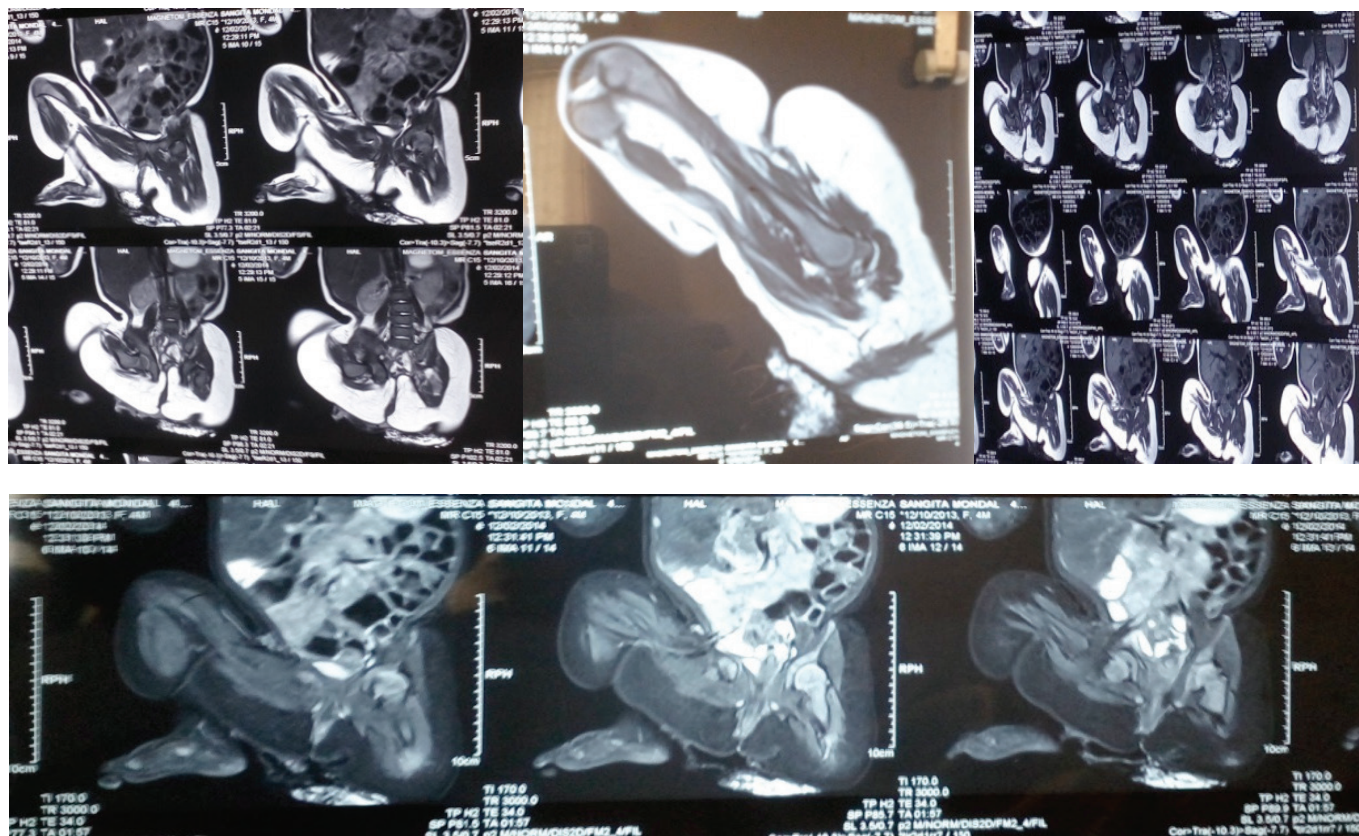
#### 3.1. Facial and Oral Manifestations

- Cleft lip and / or cleft palate in approximately 85% of patients.
- Pits or sinuses of the lower lip in 60% of patients [16].

- Congenital bands or threads of mucous membrane extending between the jaws (syngnathia) are seen in 30% of patients.
- A band between gingiva and the lower lip has been described in a few cases.
- The most obvious facial alterations are cleft lip and/or cleft palate. Filiform adhesions between the eyelids are noted in 20% of the patients [17]. Pits of the lower lip are common. Rarely choanal atresia is seen in such patients [18].

#### 3.2. Cutaneous and Musculoskeletal Anomalies

Popliteal web is the striking feature occurring in 70% of the patients. The web extends from the heel to the ischial tuberosity, limiting extension and abduction as well as rotation of the leg. Bilateral webs have been noticed in some cases, their thickness and extent can be symmetrical or asymmetrical [19]. Typically they cause flexion deformity at the knees limiting their movements. The soft tissue band associated with this syndrome can be complete or incomplete. Along the free edge of the pterygium runs a hard, inelastic subcutaneous cord or fibrous band called calcaneo-ischiadi-



**Figure 3:** MRI pictures show poorly developed muscle mass in the right thigh and soft tissue fusion between the right thigh and right leg.

cus muscle [20]. The sciatic nerve lies free within the web, deep to the fibrous band approximately half way between the free edge and the apex, being covered by a fibro muscular septum. The apex of the pterygium contains only collagen fibers, with the shortened nerves and blood vessels located deeper within the pterygium.

### 3.3. Genito-Urinary Tract

Anomalies in the male have included cryptorchidism seen in 40% of patients, ambiguous genitalia, absent/cleft, or ectopic scrotum in 35%, small penis is seen in 40% of patients, and inguinal hernia in 10% of the patients. In the female, absence or displacement of the labia majora is seen in 60%, enlarged clitoris in 20% of patients. Hypoplastic uterus has also been described. An intercrural pterygium extending between both thighs, ventral to the anus is seen in 20% of patients.

### 3.4. Anatomical Alterations

Special caution must be taken during surgery because of the altered anatomy. The muscle groups are absent or muscle insertions are abnormal. There may be a minimal pterygium of a single limb. The nerves and vessels are shortened with possible damage during limb lengthening procedures. The spectrum of anomalies may include the following.

- ✓ Hypoplasia or agenesis of digits – 20% [21].
- ✓ Varus or valgus deformities of the foot- 20% [22].
- ✓ Manifest variable syndactyly of the second to fifth toes - 50%
- ✓ In the hand, most often 3rd and 4th fingers - 15% [23].
- ✓ Ectrodactyly may rarely occur [24].
- ✓ Spina bifida occulta has been documented in 20% of patients.
- ✓ Scoliosis or lordosis in 10% [25].
- ✓ Rarely Bipartite or absent patella has been documented [26].
- ✓ Pyramidal shaped skin fold over the hallux is seen, with one vertex of the fold that extends over the nail in approximately 40% of the patients [27].
- ✓ If present in a child with cleft lip and/or palate, even in the absence of a distinct popliteal pterygium, presence of these anomalies is sufficiently distinct to make the diagnosis.

- ✓ The toe nails, most often the second, are hypoplastic and triangular in approximately 30% of patients.

## 4. DIFFERENTIAL DIAGNOSIS

It is important that popliteal pterygium syndrome is recognized and included in the differential diagnosis of both orofacial clefting with lower lip pits and other syndromes associated with pterygia. Diagnosis is important in terms of genetic counseling. Patients with VWS should be examined carefully to exclude abnormalities of the lower limbs. The popliteal pterygia make this syndrome distinctive. Neuman and Shulman described the complete expression of this syndrome with cleft palate, lip pits, oral mucosal adhesions, and ankyloblepharon [28]. Lip pits and ankyloblepharon may occur as an isolated phenomenon or in combination with cleft lip and / or cleft palate. Extreme types of bifid scrotum may occur as isolated anomalies [29].

### 4.1. Hay-Wells Syndrome

Hay-wells syndrome is one of at least 150 known types of ectodermal dysplasia (AEC syndrome) with autosomal dominant pattern of inheritance. These disorders affect tissues that arise from the ectodermal germ layer, such as skin, hair, and nerve. This is an autosomal dominant syndrome, caused by a missense mutation in the Sterile alpha motif (SAM) of the TP73L (p63) gene which encodes for a protein-protein interaction domain.

### 4.2. Ankyloblepharon-Ectodermal

Ankyloblepharon-Ectodermal dysplasia-Cleft lip/palate syndrome includes both ankyloblepharon and cleft lip or cleft palate. Pterygia of the axilla, neck and antecubital, and popliteal areas constitute multiple pterygium syndromes. Pterygia-like alterations of the lower extremities occur as part of the caudal regression complex. Antecubital pterygia are seen as an autosomal dominant trait [30]. They may also occur in association with the nail-patella syndrome.

### 4.3. Bartsocas-Papas Syndrome

Bartsocas-Papas syndrome (also known as BPS, Pterygium popliteal lethal type) is a lethal autosomal recessive inherited popliteal pterygium syndrome. Findings include low birth-weight, mental retardation, mild growth retardation, microcephaly, filiform adhesions of eyelids, corneal ulceration, hypoplastic nasal tip, microstomia, cleft lip-palate, soft-tissue syngnathia, microgn-

athia, super-numerary nipples, aplastic labia majora, bicornate uterus, and lanugo hair. Lethal PPS syndrome has renal aplasia. Anomalies of the extremities comprise popliteal pterygia, pes equino-varus, hypoplastic or absent phalanges, syndactyly of fingers and toes, and synostosis of hand bones. There are no vertebral anomalies. Death occurs at the intrauterine or neonatal stages of life.

## 5. DIAGNOSIS OF POPLITEAL PTERYGIUM SYNDROME

### 5.1. Ultrasound Examination

Prenatal diagnosis is by ultra-sonographic study [31]. Doppler ultrasound is limited by operator dependence, particularly due to difficulty posed by the contracted knees. The prenatal ultrasound identification of a cleft lip and palate, equino varus feet with severe lower limb mal-position and genital abnormalities led to the prenatal diagnosis of popliteal pterygium syndrome in a pregnant mother suspected to have a mild expression of this autosomal dominant condition. However, in sporadic cases with lack of a family history for this rare syndrome, prenatal diagnosis may be difficult to ascertain.

### 5.2. Computed Tomography

Computed tomography may be used to delineate the anatomy of the deformity. The Computed tomography accurately identifies the popliteal artery, but peroneal nerve identification may be more difficult. 3D reconstruction C.T. scans is useful guide to analyze the defects.

### 5.3. MRI

MRI plays a crucial role in presurgical evaluation of patients with popliteal pterygium syndrome, due to its excellent soft tissue resolution, especially with respect to nerves. Sciatic nerve can be located on MRI and has an important role in planning the surgical procedures. The flexion deformity, absent patella, Pterygium bands are seen as soft tissue opacities in MRI. Post-contrast fat-suppressed sagittal T1-weighted MRI will show the position of the popliteal arteries in relation to the pterygium bands. Axial and sagittal T1-weighted MRI will show the position of the peroneal nerve in relation to the pterygium bands. Angio-MRI is useful for analyzing the vasculature and is a useful guide for planning the surgery. MRI does not involve much ionizing radiation, is of particular importance to the patients in the pediatric age-group.

## 5.4. Chromosomal and Genetic Testing

Autosomal dominant popliteal pterygium syndrome is diagnosed by study of deletion/duplication analysis on IRF6 gene. Clinical genetic evaluation includes (1) diagnosis, (2) recurrence risk counseling and (3) counseling regarding prognosis.

### 5.4.1. Indications for Referral

Indications for referral for a complete genetic evaluation include (a) positive family history (b) prenatal growth deficiency (c) unexplained postnatal growth deficiency (d) developmental delay or mental retardation (e) associated major malformations and/or disorders (f) associated minor 22,23 chromosomal malformations and/or disorders inconsistent with the genetic background of the parents and (g) recognized genetic diagnosis families.

### 5.4.2. Test Method

Analysis is performed by bi-directional sequencing of the coding regions and splice sites of exons 2-9 of the IRF6 gene. Preferential sequencing of exon 4 can be done for patients with a clinical diagnosis of PPS. If no mutation is found by sequencing, targeted array CGH analysis with exon level resolution (ExonArrayDx) is done for a deletion or duplication of one or more exons of this gene. Mutations in PPS are typically missense.

### 5.4.3. Whole Exome Sequencing

The exome is comprised of all of the protein-encoding exons in the genome. The exome accounts for only 1% of the entire genome, but mutations in the exons account for many genetic disorders. Most genetic tests analyze only one gene at a time. Whole exome sequencing (WES) examines the majority of exons and exon/intron boundaries of most of the genes at one time. Approximately 25% of individuals who have whole exome sequencing receive a diagnosis or a suspected diagnosis from the test.

#### 5.4.3.1. Indications:

- The patient's symptoms or family history suggest a genetic etiology but does not correspond with a specific genetic disorder.
- The patient has symptoms of a well-defined genetic disorder that is caused by multiple genes (genetic heterogeneity) for which a multi-gene panel is not clinically available.
- The patient likely has a genetic disorder but clinical genetic testing did not yield a genetic diagnosis.



- The patient's clinical presentation is unclear or atypical and there are multiple genetic conditions in the differential diagnosis.

#### 5.4.4. Test Sensitivity

Fifty percent of individuals with Van der Woude syndrome and 85% of individuals with PPS exhibit mutations in the *IRF6* gene.

#### 5.4.5. Amniotic Fluid Analysis

Prenatal Diagnosis: 10 mL amniotic fluid, 5 mg chorionic villous sampling (CVS), or cultured amniocytes accepted for analysis: 2 T25 flasks.

#### 5.4.6. Blood

A single tube with 1-5 mL whole blood in EDTA must be submitted for study. Submission of a venous blood sample for Gene deletion/duplication testing (ExonArrayDx)

#### 5.4.7. Buccal Brushes

Can be used as an alternative to blood for IRF sequencing only.

### 5.5. Genetic Counseling

*IRF6*-related disorders are inherited in an autosomal dominant manner. Most individuals diagnosed with an *IRF6*-related disorder have an affected parent; however, penetrance is incomplete and *de novo* mutations have also been reported. If a parent of the proband is affected or has an *IRF6* pathogenic variant, the risk to the sibs of inheriting the pathogenic variant is 50%. Molecular genetic testing is used for prenatal diagnosis for pregnancies at increased risk, if the pathogenic variant has been identified in an affected family member. Prenatal ultrasound examination may detect a cleft lip with/without cleft palate in some fetuses later in the second trimester

## 6. SURGICAL MANAGEMENT OF POPLITEAL PTERYGIUM SYNDROME

A multidisciplinary approach involving various specialties is important in the Management of these difficult problems. The team includes

- Physician,
- Orthopedic surgeon,
- Physiotherapists and
- Plastic surgeon.

### 6.1. Surgical Management

Conservative treatment methods such as serial casting or traction have been unsatisfactory. Surgical resection of pterygium bands is essential to relieve the contracture. The key structures including popliteal arteries and peroneal nerves lie abnormally within or just adjacent to the pterygium. Precise anatomical localization of these structures is essential before surgical resection is planned to avoid damage to the vital structures. Surgical lengthening of the soft tissues (skin, muscles and ligaments) by resection of fibrous bands and Z-plasty is the most preferred technique. When the sciatic nerve is displaced into the webbing and attached to the fibrous tissues, nerve grafting is required following soft tissue lengthening. Oppenheim *et al.* reported that excision of fibrous bands and Z-plasty were possible in 20% of cases of PPS and the rest of the cases required secondary operations such as femoral extension osteotomy, femoral shortening or amputation due to severe adhesion to the sciatic nerve [32]. Considering the patient's age and that potential future growth may cause severe shortening of the lower extremity and the leg, hamstring release at the ischial tuberosity, tenotomy of the flexor hallucis longus and Achilles tendon Z-lengthening on the ankle may be done. This is followed by gradual lengthening using an Ilizarov external fixator that is commonly used for correction of shortening or deformity and also for the treatment of joint contractures.

Gillen *et al.* reported a rebound contracture of 15-30 degrees following successful treatment of joint contractures with Ilizarov technique [33]. The patients were advised a knee-ankle-foot orthosis postoperatively to prevent relapse of contractures [34]. Gillen *et al.* reported that gradual soft tissue lengthening using an Ilizarov external fixator could lead to complications such as subluxation or dislocation of the knee, fracture or temporary loss of sensation. The pin tract infection may be treated with oral antibiotics. Gradual soft tissue lengthening with an Ilizarov external fixator can be one of the options when excision of fibrous band and Z-plasty are not possible due to adhesion to the nerves or blood vessels in the popliteal pterygium but this procedure has high risk of recurrence of contracture.

### 6.2. Secondary Procedures in Popliteal Pterygium Syndrome

Femoral extension osteotomy, femoral shortening or knee arthrodesis may be performed depending on the patient's functional requirements. In severe cases, am-

putation also becomes an option. Unwanted extension of pubic hair onto the inner thigh was mentioned as a common complaint by the patients requiring electrolysis therapy. Services of pediatric dentistry, orthodontia, speech therapy, feeding and hearing evaluation, physical therapy, and orthopedic care are also an integral part of the management program.

### 6.3. Prevention of Secondary Complications

Timely treatment of otitis media due to Eustachian tube dysfunction to prevent secondary hearing loss, evaluations by a speech-language pathologist can aid in determining if speech therapy or other interventions are appropriate for a child with secondary hearing loss.

### 6.4. Surveillance

Parameters for surveillance for cleft lip and/or cleft palate have been published by the American Cleft Palate-Craniofacial Association.

## 7. DISCUSSION

Popliteal pterygium syndrome is a rare genetic condition characterized by popliteal webbing, craniofacial anomalies, genitourinary anomalies and skeletal anomalies. *Van der Woude syndrome, a mutation in the interferon regulatory factor 6 gene, also shares most of the features as PPS.* Van der Woude syndrome and popliteal pterygium syndrome are allelic and have phenotypic overlap as both syndromes are due to genetic mutations that affect interferon regulatory factor 6 gene. Intervalveolar synechia occurs in 33% to 43% of patients with PPS. Bartsocas and Papas postulated that PPS can be inherited in an autosomal dominant and in an autosomal recessive manner; autosomal dominant PPS is more common and it shows variable penetrance, but autosomal recessive PPS occurs in patients who are born to unaffected parents and it is associated with more severe anomalies and mental retardation and they survive only 9 weeks of life [35]. Giannotti *et al.* [36] concluded PPS is an autosomal dominant disorder caused by interferon regulatory factor 6 gene mutations and postulated that those cases should have been diagnosed as another disorder with symptoms that were similar but more severe than those of popliteal pterygium syndrome [36]. Popliteal pterygium syndrome can be diagnosed based on the presence of cleft lip, cleft palate, genital hypoplasia and popliteal webbing, but care should be taken to differentiate it from multiple pterygium syndrome, arthrogryposis multiplex congenita, sacral agenesis and myelomeningocele.

## 8. MULTIPLE PTERYGIUM SYNDROMES

In the past, the clinical and laboratory findings of Multiple Pterygium syndrome have been described under the diagnosis of arthrogryposis multiplex congenita, and Bonnevie-Ullrich syndrome. Recently they are classified as Multiple Pterygium syndrome (Escobar syndrome OMIM#26500). Escobar variant multiple pterygium syndromes (EVMPS) is also known in different synonyms as Escobar syndrome, Multiple pterygium syndrome, Non-lethal type pterygium syndromes, Multiple pterygium syndrome, Pterygium Colli Syndrome and Pterygium Universale. Multiple pterygium syndromes are characterized by pterygia of several joints such as the axilla, the volar aspect of the elbow and the interphalangeal areas. The patients with multiple pterygium syndromes present with other associated deformities.

### 8.1. Molecular Genetics

Multiple pterygium syndromes are a phenotypically and genetically heterogeneous group of rare Mendelian conditions characterized by multiple pterygia, scoliosis and congenital contractures of the limbs. *MPS typically segregates as an autosomal recessive disorder.* Rare instances of autosomal dominant transmission have been reported. Camptodactyly of the hands, vertebral fusions, and scoliosis are reported to be associated features. Exome sequencing studies identified predicted protein-altering mutations in embryonic myosin heavy chain (*MYH3*) in three families. *MYH3* mutations underlie distal arthrogryposis types 1,2A and 2B, all mutations reported occur in the head and neck domains. In contrast, *two of the mutations found to cause MPS occurred in the tail domain.* The vertebral fusions in persons with MPS coupled with evidence of *MYH3* expression in bone suggests that embryonic myosin plays a role in skeletal development.

The exact etiology of Escobar syndrome is not known. Hoffmann *et al.* suggested that CHRNG gene of AChR subunits could be responsible for the arthrogryposis multiplex congenita (multiple congenital contractures) observed in this syndrome [37]. This receptor has 5 subunits - 2 alpha, 1 beta, 1 delta and 1 gamma/epsilon unit. The gamma subunit is replaced by the epsilon in later fetal or perinatal life. In Escobar syndrome, gamma subunit of acetylcholine receptor, which has a role in the muscle-relaxant effect was muted. Phenotype-Gene relationship of Escobar syndrome is located in 2q37.1 chromosome (Table 2). Absence of gamma subunit in fetal life causes reduced fetal move-

**Table 2: Phenotype-Gene Relationships**

Location	Phenotype	Phenotype MIM Number	Inheritance	Phenotype Mapping Key	Gene/Locus	Gene/Locus MIM Number
2q37.1	Escobar syndrome	265000	AR	3	CHRNA3	100730

ment, which is responsible for the contractures. Michalk described mutations in the fetal expressed  $\gamma$  subunit (*CHRNA3*) of AChR were found in both lethal MPS and Escobar syndrome. The nonlethal Escobar variant of MPS (EVMPS) is caused by homozygous or compound heterozygous mutation in the *CHRNA3* gene (100730), which encodes the gamma subunit of acetylcholine receptor (AChR), on chromosome 2q [38].

Morgon *et al.* [39] demonstrated that both the lethal and non-lethal (Escobar) variants of multiple pterygium syndrome are caused by mutations in the gamma or fetal subunit of the nicotinic acetylcholine receptor (*CHRNA3*; 100730) [39].

## 8.2. Clinical Features of Multiple Pterygium Syndromes

The most consistent malformations present in Escobar Syndrome are

1. Pterygia of the neck (100%),
2. Antecubital (90%),
3. Popliteal areas (90%),
4. Camptodactyly of fingers (84%),
5. Syndactyly (74%),
6. Numerous joint flexion contractures (74%) and
7. Foot deformities (74%).

Other occasional features associated are umbilical hernia (26%), inguinal hernia (26%) and congenital hip dislocation (21%). MPS is also called pterygium colli syndrome, Escobar syndrome and pterygium syndrome [40]. The pterygium syndromes are a clinically heterogeneous group of at least 15 different entities, of which the multiple pterygium syndrome is one of the most frequently observed. It is a rare condition, characterized by multiple congenital joint contractures and multiple skin webs. Multiple pterygium syndromes are generally transmitted by an autosomal recessive pattern of inheritance; however, autosomal dominant or X-linked dominant inheritance patterns have also been described. Chromosomal analyses of the patients reveal a non-mosaic 47, XXY karyotype; they did not show the main clinical signs of Klinefelter syndrome.

## 8.3. Escobar Syndrome

Escobar syndrome presents with the following features

- Intrauterine growth restriction,
- Abnormal facial features,
- Widespread pterygium that result in joint contractures,
- Ptosis,
- Cryptorchidism,
- Patellar dysplasia and foot deformities
- Inguinal hernias and cranial ventriculomegaly have also been established as components of Escobar syndrome [41].

## 8.4. Genetic Basis of Multiple Pterygium Syndromes

Multiple pterygium syndromes (MPS) are a phenotypically and genetically heterogeneous group of rare Mendelian conditions characterized by multiple pterygia, scoliosis and congenital contractures of the limbs. Multiple pterygium syndromes typically segregate as an autosomal recessive disorder but rare instances of autosomal dominant transmission have been reported. While several mutations causing recessive multiple pterygium syndromes have been identified, the genetic basis of dominant multiple pterygium syndromes remain unknown. Four families with dominant transmission of multiple pterygium syndromes characterized by pterygia, camptodactyly of the hands, vertebral fusions, and Scoliosis have been documented. Matolcsy [42] clearly defined the multiple pterygium syndromes that consist of growth retardation, multiple pterygia involving the neck, fingers, and antecubital, popliteal, and inter-crural areas, and Cleft palate [43]. These were previously diagnosed as arthrogryposis [44] or Noonan syndrome [45].

Nearly 70 cases of Escobar syndrome have been reported to date. Nearly 75% of affected children are small for their gestational ages. Celikoz clearly defined Escobar syndrome [46]. Thompson *et al.* reviewed the evolution of the phenotype [47]. The syndrome has



autosomal recessive inheritance. Parental consanguinity has been reported in the patients being more common among Arabs. Recurrent chest infections, as the results of congenital kyphoscoliosis, may result in early deaths [48]. Lethal form of multiple pterygium syndromes is characterized by multiple pterygium, hydrops fetalis and /or Hygroma coli and is associated with pulmonary hypoplasia. It can be diagnosed by ultrasonography performed in the second trimester of pregnancy and stillbirths are common in this group of patients.

## 8.5. Clinical Features

### 8.5.1. Facial features

- ✚ The palpebral fissures are mildly down slanting in 50% of the patients.
- ✚ There is mild ptosis of the lids in 30% of patients.
- ✚ Epicanthal folds in 15%
- ✚ Approximately 50% of the patients have puffiness around the eyes.
- ✚ The mandible is small in 60% of patients.
- ✚ Central neck web is noted in few patients.

### 8.5.2. Musculoskeletal Alterations

Growth is usually retarded below the third percentile; the patient's adult height rarely exceeding 135cm. Body asymmetry has been noted. The popliteal pterygia noted in 45%, causing difficulty in walking and affect posture and gait. Pterygia occur in the cervical area in 95% of patients. Cervical pterygia may resemble those seen in Turner and Noonan syndromes. Rarely do they completely surround the neck. A pterygium that extends from the chin to the sternum is seen in 15% of the patients. The axillae (55%) and ante cubital fossae (35%) are the other sites of webbing. Intercrural webs are found in 40% of both males and females. In the presence of an intercrural web in male, the penis and scrotum are retro positioned and may be associated with cryptorchidism and/or inguinal hernia. In the female patients, the labia majora may be absent. There is mild soft-tissue syndactyly between the fingers in 50% of the patients. Flexion deformity of the digits, with the thumbs being flexed and apposed occurs in 60% of the patients. Talipes calcaneo valgus, either unilateral or bilateral, and rocker-bottom feet have been noted in 35%. Congenital Kyphoscoliosis and other vertebral anomalies- failure of posterior fusion of vertebrae, fusion of cervical vertebrae) are found in 60% of patients.

### 8.5.3. Associated Anomalies

Routine cardiac examination detected congenital heart defects in 25% of patients with Escobar syndrome. Cardiac evaluation must be done in all patients with pterygia syndrome

## 8.6. Radiographic Changes Include

- ✚ Vertebral segmentation anomalies such as fusion of cervical vertebrae,
- ✚ Rib anomalies (25%),
- ✚ Tall narrow vertebral bodies (30%),
- ✚ Vertical talus with talipes calcaneo valgus or equino- varus (65%),
- ✚ Camptodactyly of fingers and toes (65%) and
- ✚ The patellae may be absent.

## 8.7. Discussion

The first case of Escobar syndrome reported in India by Victor Escobar in 1978. A five-year old girl from Vellore with features of absent uvula, ulceration of the lower eyelids, conjunctival hyperplasia and pterygia of popliteal region. Conductive deafness was said to be a consistent part of this syndrome according to Thompson *et al.* [46]. Escobar syndrome is a rare autosomal recessive genetic disorder and rarely can be autosomal dominant. Sporadic inheritance has also been suggested. The oral manifestations recorded in Escobar syndrome patient include microstomia, mandibular retrognathism, high arched palate, limited mouth opening and multiple carious teeth. Escobar syndrome can be diagnosed prenatally during the 23rd week of pregnancy by using two-dimensional ultrasound scan.

## 8.8. The Differential Diagnoses for this Syndrome are

- Popliteal pterygium syndrome: pterygia of the neck, antecubital area and axilla are not present but it includes cleft lip, lip pits, syngnathia and ankyloblepharon.
- Antecubital pterygium syndrome: includes bilateral antecubital webbing and absent long head of triceps. Both these syndromes are inherited in an autosomal dominant manner.

## 8.9. Treatment

Treatment of multiple popliteal pterygium syndromes involves multidisciplinary management including the

services of Physician, Orthopedic surgeon, Physio-therapist and Plastic surgeon for management of limb and other deformities. The long-term complications include hearing loss and infertility in males. Genetic counseling and in utero detection remains the mainstay of treatment.

## 9. CONCLUSION

Surgical treatment of Pterygium syndromes are difficult to treat and careful preservation of neurovascular structures is important for preservation of functional improvement. Multiple stages of surgical procedures with multi-disciplinary approach are required for rehabilitation of patients with pterygia syndromes. A complete ante-natal evaluation of patients is the key to diagnosis in those suspected with genetic abnormalities. Early detection of the genetic disorder and genetic counseling are important aspects of treatment of these rare genetic disorders.

## REFERENCES

- [1] Trelat U. Sur un vice conformation tres-rare de la levere - inferieure. *J Med Chir Prat.* 1869; 40: 442-445.
- [2] Gorlin RJ, Sedano HO, Cervenka J. Popliteal pterygium syndrome. A syndrome comprising cleft lip palate, popliteal and intercrural pterygia, digital and genital anomalies. *Pediatrics* 1968; 41: 503-509.
- [3] Rintala A, Lahti A. The facio-genito-popliteal syndrome. *Scand J Plast Reconstr Surg.* 1970; 4: 67-71.  
<http://dx.doi.org/10.3109/02844317009038446>
- [4] Escobar V. Popliteal pterygium syndrome: A phenotypic and genetic analysis. *J Med Genet.* 1978; 15: 35-42.  
<http://dx.doi.org/10.1136/jmg.15.1.35>
- [5] Frohlich G. Popliteal pterygium syndrome: Report of a family. *Pediatric* 1977; 90: 91-93.  
[http://dx.doi.org/10.1016/S0022-3476\(77\)80775-0](http://dx.doi.org/10.1016/S0022-3476(77)80775-0)
- [6] Spranger S, Spranger M, Meinck HM, Tariverdian G. Two sisters with Escobar syndrome. *Am J Med Genet.* 1995; 57(3): 425-428.  
<http://dx.doi.org/10.1002/ajmg.1320570312>
- [7] Deskin RW, Sawyer DG. Popliteal pterygium syndrome. *Int J Pediatr Otorhinolaryngol.* 1988; 15: 11-22.  
[http://dx.doi.org/10.1016/0165-5876\(88\)90046-8](http://dx.doi.org/10.1016/0165-5876(88)90046-8)
- [8] Schutte B. Microdeletions at the chromosome bands 1q32-q41 as a cause of van der woude syndrome. *Am J Med Genet.* 1999; 84:145-150.  
[http://dx.doi.org/10.1002/\(SICI\)1096-8628\(19990521\)84:2<145::AID-AJMG11>3.0.CO;2-L](http://dx.doi.org/10.1002/(SICI)1096-8628(19990521)84:2<145::AID-AJMG11>3.0.CO;2-L)
- [9] Hunter A. The popliteal pterygium syndrome: Report of a new family and review of the literature. *Am J Med Genet.* 1990; 36: 196-208.  
<http://dx.doi.org/10.1002/ajmg.1320360213>
- [10] Bamshad M, Jorde LB, Carey JC. A revised and extended classification of the distal arthrogryposes. *Am J Med Genet.* 1996; 65: 277-281.  
[http://dx.doi.org/10.1002/\(SICI\)1096-8628\(19961111\)65:4<277::AID-AJMG6>3.0.CO;2-M](http://dx.doi.org/10.1002/(SICI)1096-8628(19961111)65:4<277::AID-AJMG6>3.0.CO;2-M)
- [11] Kondo S, Schutte BC, Richardson RJ, Bjork BC, Knight AS, Watanabe Y, *et al.* Mutations in IRF6 cause Van der Woude and popliteal pterygium syndromes. *Nat Genet.* 2002; 32: 285-289.  
<http://dx.doi.org/10.1038/ng985>
- [12] Lees MM, Winter RM, Malcom S, Saal HM, Chitty L. Popliteal pterygium syndrome: a clinical study of three families and report of linkage to the Van der Woude syndrome locus on 1q32. *J Med Genet.* 1999; 36: 888-892.
- [13] de Lima RL, Hoper SA, Ghassibe M, Cooper ME, Rorick NK, Kondo S, *et al.* Prevalence and non random distribution of exonic mutations in interferon regulatory factor 6 in 307 families with Van der Woude syndrome and 37 families with popliteal pterygium syndrome. *Genet Med.* 2009; 11: 241-247.  
<http://dx.doi.org/10.1097/GIM.0b013e318197a49a>
- [14] Leslie EJ, Standley J, Compton J, Bale S, Schutte BC, Murray JC. Comparative analysis of IRF6 variants in families with Van der Woude syndrome and popliteal pterygium syndrome using public whole-exome databases. *Genet Med.* 2013; 15: 338-344.  
<http://dx.doi.org/10.1038/gim.2012.141>
- [15] Wu T, Liang KY, Hetmanski JB, Ruczinski I, Fallin MD, Ingersoll RG, *et al.* Evidence of gene-environment interaction for the IRF6 gene and maternal multivitamin supplementation in controlling the risk of cleft lip with/without cleft palate. *Hum Genet.* 2010; 128: 401-410.  
<http://dx.doi.org/10.1007/s00439-010-0863-y>
- [16] Hecht F, Jarvinen JM. Heritable Dysmorphic syndrome with normal intelligence. *J Pediatr.* 1967; 70: 927-935.  
[http://dx.doi.org/10.1016/S0022-3476\(67\)80265-8](http://dx.doi.org/10.1016/S0022-3476(67)80265-8)
- [17] Khans N. Intra familial variability of popliteal pterygium syndrome: A family description. *Cleft Palate J.* 1986; 23: 233-236.
- [18] Kind HP. Popliteales Pterygium-syndrom. *Helv Paediatr Acta* 1970; 25: 508-516.
- [19] Tuerk D, Edgerton MT. The surgical treatment of congenital webbing (pterygium) of the popliteal area. *Plast Reconstr Surg.* 1975; 56: 339-344.  
<http://dx.doi.org/10.1097/00006534-197509000-00020>
- [20] Addison A, Webb PJ. Flexion contractures of the knee associated with popliteal webbing. *J Pediatr Orthoped.* 1983; 3: 376-379.  
<http://dx.doi.org/10.1097/01241398-198307000-00019>
- [21] Champion R, Cregan JCF. Congenital popliteal webbing in siblings: Report of two cases. *J Bone Joint Surg Br.* 1969; 41: 355-359.
- [22] Basch K. Einweiterer Fall von sog. Flughautbildung. *Prag Medwscr.* 1891; 16: 572-573 and 1892; 17: 287-291.
- [23] Baja PS, Bailey BM. Ectopic scrotum: A case report. *Br J Plast Surg.* 1969; 22: 87-89.  
[http://dx.doi.org/10.1016/S0007-1226\(69\)80096-2](http://dx.doi.org/10.1016/S0007-1226(69)80096-2)
- [24] Aron NK. The popliteal web syndrome. *Eur J Plast Surg.* 1988; 11: 93-94.  
<http://dx.doi.org/10.1007/BF00299222>
- [25] Klein D. Uncurieux syndrome h1 erl editaire: Cheilo-palato-schizis avec "s-tules delal" evreinfl erieure associ e a une synd-actylie, une onychodysplasie parti-culiere, un ptl erygion popliti eunilatl eraleet des pieds varus l equins. *J Genet Hum.* 1962; 11: 65-71.
- [26] Pfeiffer RA. Das Kniepterygium-syndrom. Ein autosomal dominant vererbtes Missbildungssyndrom. *Z Kinderheilkunde* 1970; 108: 103-116.  
<http://dx.doi.org/10.1007/BF00439878>
- [27] Baruthcu A. A case with popliteal pterygium syndrome and its surgical treatment. *Eur J Plast Surg.* 1990; 13(4): 182-184.  
<http://dx.doi.org/10.1007/BF00236376>

- [28] Neuman Z, Shulman J. Congenital sinuses of the lower lip. *Oral Surg.* 1961; 14: 1415-1420.  
[http://dx.doi.org/10.1016/0030-4220\(61\)90243-2](http://dx.doi.org/10.1016/0030-4220(61)90243-2)
- [29] Gorlin RJ. Popliteal pterygium syndrome: A syndrome comprising cleft lip/palate, popliteal and intercrural pterygia, digital and genital anomalies. *Pediatrics* 1968; 41: 503-509.
- [30] Ozgur FF. Antecubital pterygium syndrome. *Eur J Plastsurg.* 1993; 16: 10-11.
- [31] Perrotin F. Prenatal ultrasonographic diagnosis of the popliteal pterygium syndrome. *Prenat Diagn.* 2000; 20: 501-504.  
[http://dx.doi.org/10.1002/1097-0223\(200006\)20:6<501::AID-PD862>3.0.CO;2-X](http://dx.doi.org/10.1002/1097-0223(200006)20:6<501::AID-PD862>3.0.CO;2-X)
- [32] Oppenheim WL, Larson KR, McNabb MB, Smith CF, Setoguchi Y. Popliteal pterygium syndrome: an orthopaedic perspective. *J Pediatr Orthop.* 1990; 10(1): 58-64.
- [33] Gillen JA, Walker JL, Burgess RC, Stevens DB. Use of Ilizarov external fixator to treat joint pterygia. *J Pediatr Orthop.* 1996; 16(4): 430-7.  
<http://dx.doi.org/10.1097/01241398-199607000-00003>
- [34] Parikh SN, Crawford AH, Do TT, Roy DR. Popliteal pterygium syndrome: implications for orthopaedic management. *J Pediatr Orthop B.* 2004; 13(3): 197-201.
- [35] Bartsocas CS, Papas CV. Popliteal pterygium syndrome: evidence for a severe autosomal recessive form. *J Med Genet.* 1972; 9(2): 222-6.  
<http://dx.doi.org/10.1136/jmg.9.2.222>
- [36] Giannotti A, Digilio MC, Standoli L, Zama M, Dallapiccola B. New case of Bartsocas-Papas syndrome surviving at 20 months. *Am J Med Genet.* 1992; 42(5): 733-5.  
<http://dx.doi.org/10.1002/ajmg.1320420522>
- [37] Hoffmann K, Muller JS, Stricker S, Megarbane A, Rajab A, Lindner TH, *et al.* Escobar syndrome is a prenatal myasthenia caused by disruption of the acetylcholine receptor fetal gamma subunit. *Am J Hum Genet.* 2006; 79(2): 303-312.  
<http://dx.doi.org/10.1086/506257>
- [38] Michalk A, Stricker S, Becker J, Rupps R, Pantzar T, Miertus J, *et al.* Acetylcholine receptor pathway mutations explain various fetal akinesia deformation sequence disorders. *Am J Hum Genet.* 2008; 82(2): 464-76.  
<http://dx.doi.org/10.1016/j.ajhg.2007.11.006>
- [39] Morgon NV, Brueton LA, Cox P, Tolmie J, Pasha S, Morton JE. Mutations in the embryonal subunits of the acetylcholine receptor (CHRNA) cause lethal and Escobar variants of multiple pterygium syndrome. *Am J Hum Genet.* 2006; 79(2): 390-395.  
<http://dx.doi.org/10.1086/506256>
- [40] Herold HZ, Shmueli G, Baruchin AM. Popliteal pterygium syndrome. *Clin Orthop Relat Res.* 1986; 209: 194-7.  
<http://dx.doi.org/10.1097/00003086-198608000-00027>
- [41] McCall RE, Budden J. Treatment of multiple pterygium syndrome. *Orthopedics* 1992; 15(12): 1417-22.
- [42] Matolcsy T. Ueber die chirurgische Behandlung der angeborenen Flughaut. *Langenbeck Arch Klin Chir* 1936; 185: 675-681.
- [43] Srivastava RN. Arthrogryposis multiplex congenita: Case reports of two siblings. *Clin Pediatr.* 1968; 7: 691-4.  
<http://dx.doi.org/10.1177/000992286800701112>
- [44] Gorlin RJ, Cohen MM, Hennekam RC. Chromosomal syndromes: Common and/or well-known syndromes. *Syndromes of the Head and Neck* (4th ed). Oxford:Oxford University Press; 2001; 62-66.
- [45] Celikoz B. A variant of Noonan's syndrome. *Eur J Plast Surg.* 1997; 20: 157-560.  
<http://dx.doi.org/10.1007/BF01002053>
- [46] Thompson EM, Donnai D, Baraitser M, Hall CM, Pembrey ME, Fixsen J. Multiple pterygium syndrome evolution of the phenotype. *J Med Genet.* 1987; 2(4): 733-49.  
<http://dx.doi.org/10.1136/jmg.24.12.733>
- [47] Herzenberg JE, Davis JR, Paley D, Bhav A. Mechanical distraction for treatment of severe knee flexion contractures. *Clin Orthop Relat Res.* 1994; 301: 80-8.
- [48] Saleh M, Gibson MF, Sharrard WJ. Femoral shortening in correction of congenital knee flexion deformity with popliteal webbing. *J Pediatr Orthop.* 1989; 9(5): 609-11.  
<http://dx.doi.org/10.1097/01241398-198909010-00020>