

Customized Osteomesh Cranioplasty

C.N. Yogishwarappa, S. Srinivasan, S.H. Teoh, A. Vijayakumar* and M. Ishwar

The Bangalore Medical College and Research Institute, Krishna Rajendra Road, Fort, Kalasipalyam, Bengaluru, Karnataka 560002, India

Abstract: Cranioplasty, one of the oldest surgical procedures used to repair cranial defects, has undergone many revolutionary changes over time to find the ideal material to improve patient outcome. The surgical challenge in repairing large calvarial defects is known to craniofacial surgeons. Ongoing researches on various cranioplasty materials continue with the help of recent technology. Stem cell experiments and development of morphogenic proteins are expected to take the lead in future. With the aid of Computer Aided Designing technology, all currently used alloplastic materials can be custom made for even large skull defect. We present a case of young female patient following trauma underwent craniotomy and complicated with bone graft loss. Patient initially underwent cranioplasty using a PMMA implant, inspite of its excellent tensile strength was not proven to be effective it sustained fracture and got exposed. A customized osteomesh of polycaprolactone (PCL) with a titanium scaffold with bone morphogenic protein (BMP) was impregnated with stem cells was used in cranioplasty. This aided in osseointegration, which was later proved by imaging. Empirically, there has been no ideal material for cranioplasty; however, materials that are strong, resistant to infection, radiolucent, inexpensive, and able to reincorporate with a patient's craniotomy defect will offer the greatest advantages for such patients and hence PCL with such qualities proves to be a good alternative.

Keywords: Cranioplasty, Composite graft, Osteomesh, Stem cells.

1. INTRODUCTION

Large defects of the skull may result from congenital deformities, trauma, or decompressive craniectomies, but most commonly occur because of bone flap loss resulting from infection. In addition to the aesthetic deformities, large defects in the skull may expose a significant area of the brain and prone for trauma. However, restoration and recovery of a skull defect continue to be a challenge to craniofacial surgeons and neurosurgeons. Many operative techniques and implant materials are being used to reconstruct the framework of the skull.

2. CASE REPORT

A 13-year old female was involved in a road traffic accident in which both her parents were killed. She was brought to casualty with severe head injury GCS 6/15. A plain Computer tomography of brain showed a large Fronto temporo parietal acute subdural hematoma (Figure 1). Patient underwent a right decompressive craniotomy and hematoma evacuation (Figure 2). Due to severe brain edema the bone flap was banked in abdomen. Patient made significant recovery over 6 weeks, the banked bone flap was replaced back with a resultant cranial defect measuring 4X2 cm inferiorly (Figure 3). After about three, month patient developed ulceration over the scalp with discharge and bone exposure. Further investigation revealed osteomyelitic

changes in the bone flap, the bone was debrided and patient was administered a course of antibiotics (Figure 4). After six weeks the cranial defect was reconstructed with titanium reinforced poly methyl metha acrylate implant (Figure 5). After about three months the flap edge started to breakdown and the implant was exposed. A decision was made to remove the infected implant and wound closed primarily (Figure 6). A tissue expander placed over the vertex and scalp skin expanded over month time. A custom-made polycaprolactone scaffold with titanium reinforcement was ordered. A 3 D printed skull model was made to demonstrate the defect (Figure 7) and help design the Osteomesh (Figure 8).

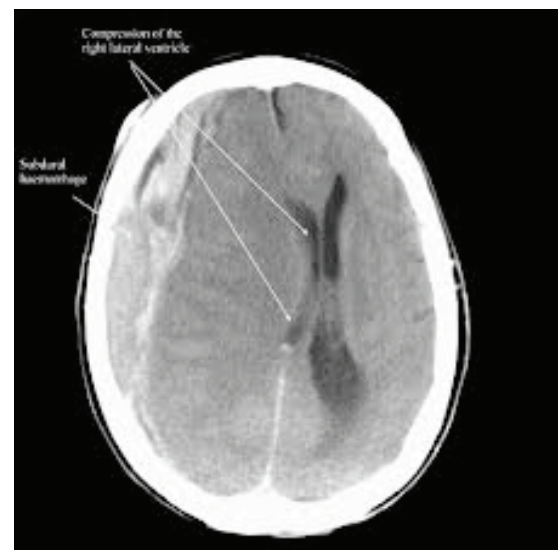

Figure 1: CT Brain showing FTP acute Subdural hematoma.

*Address correspondence to this author at #128 Vijay Doctors Colony Konanakunte Bangalore 560062, India; Tel: 9980579089; E-mail: abhishekbmc@yahoo.co.in

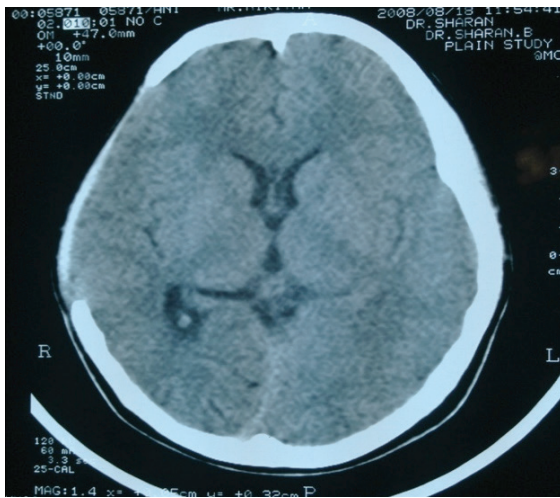


Figure 2: CT brain following SDH evacuation.

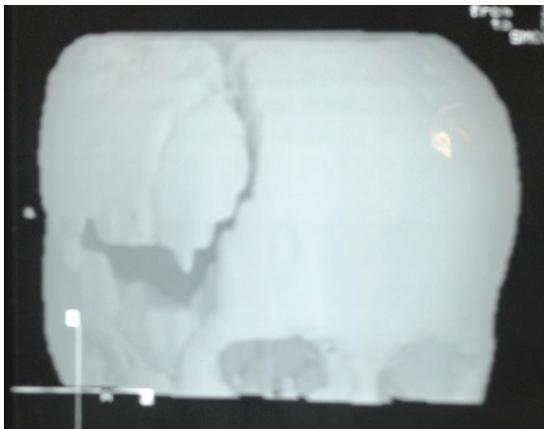


Figure 3: 3D CT Showing replaced bone flap with inferior defect.

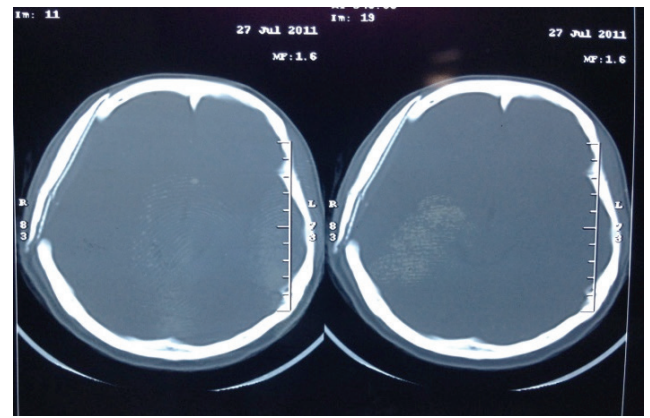


Figure 5: Defect reconstructed with Titanium reinforced PMMA implant.

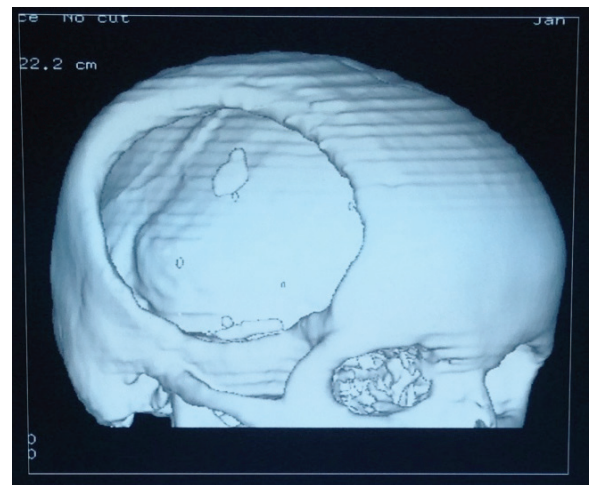


Figure 6: 3 D CT showing defect after implant removal.

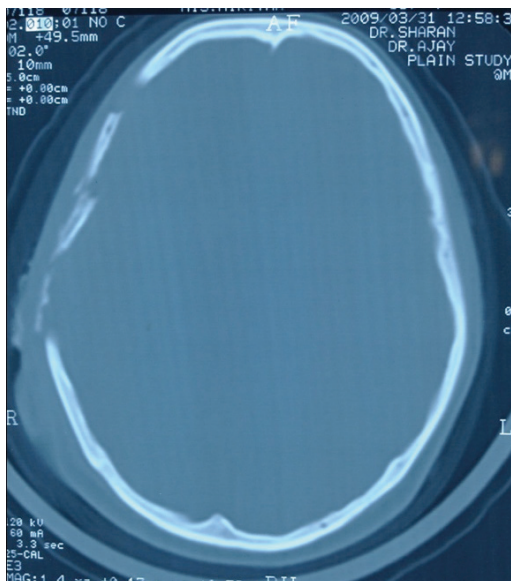


Figure 4: Osteomyelitis of Bone flap.




Figure 7: 3D printed skull model showing the defect.




Figure 8: Custom made Osteomesh.

A day prior to surgery the bone marrow was harvested from iliac crest and stem cells extract prepared. The patient was taken up for reconstruction skin flaps designed and expander removed (Figure 10). The osteomesh was impregnated with Stem cells. The bone edges were freshened (Figure 9) and the Osteomesh was fixed to surrounding bone the titanium anchors (Figure 10). Pericranial flaps were elevated (Figure 11) from either side of defect and sutured over the Osteomesh (Figure 12). Skin was closed in layers. Post-operative 3D CT showed good approximation of mesh and defect (Figure 13). During the post-operative period patient developed collection below the flap, which settled conservatively. Further post-operative course was uneventful. At 6 weeks the cranial deformity was well corrected (Figure 14). At 18 months follow-up the CT scan shows maintenance of contour and areas of bone growth into the mesh (Figure 16). The patient is pleased with the reconstruction (Figure 15).

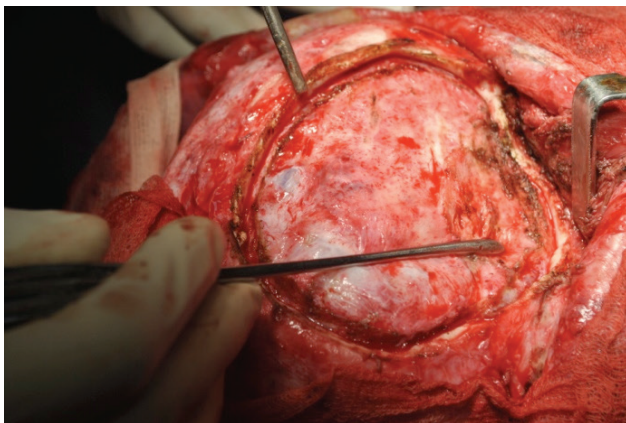


Figure 9: Bone defect edges freshened.

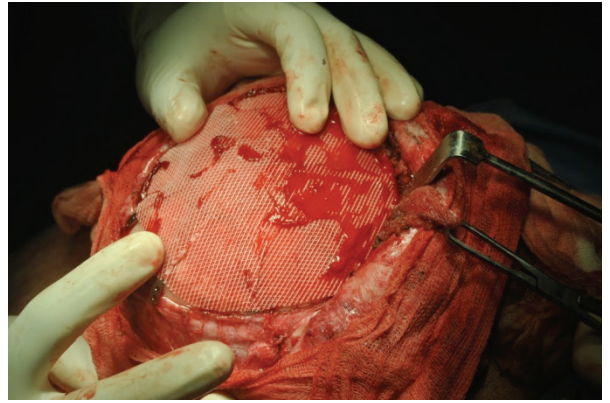


Figure 10: Osteomesh fitted to defect and fixed.

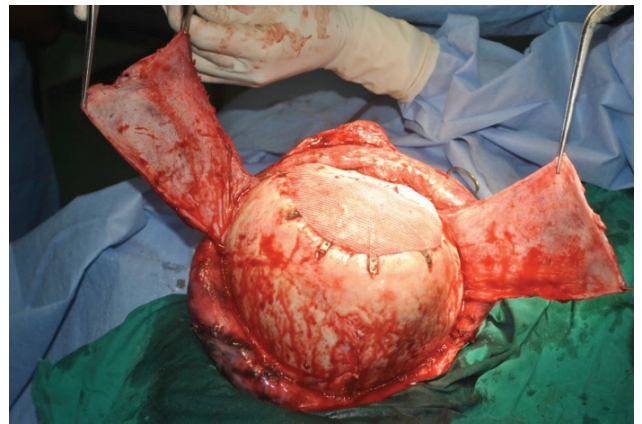

Figure 11: Elevation of pericranial flaps.

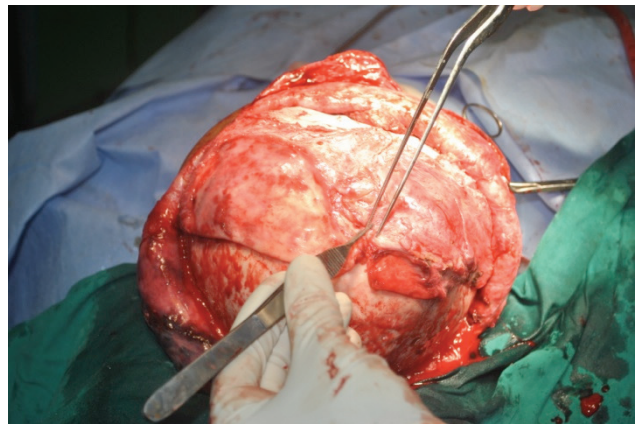


Figure 12: Pericranial flaps sutured over Osteomesh.

3. DISCUSSION

Cranioplasty is the surgical techniques to repair cranial defects to achieve both cosmetic and functional results. The history of cranioplasty dates back to over 7000 B.C [1]. In the 19th century, the use of bone from different donor sites, such as ribs or tibia, gained wide

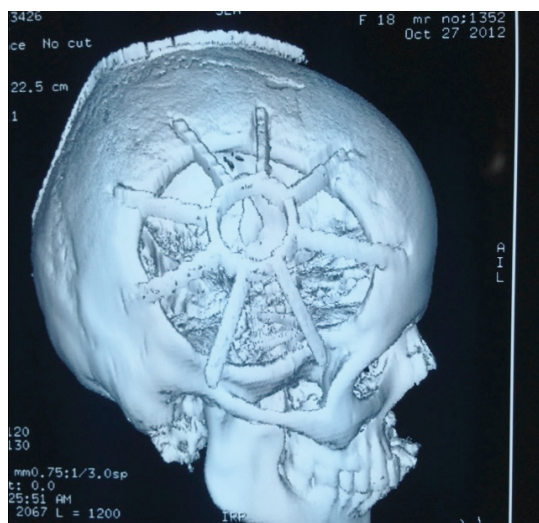


Figure 13: 3D CT showing well aligned Osteomesh over defect.

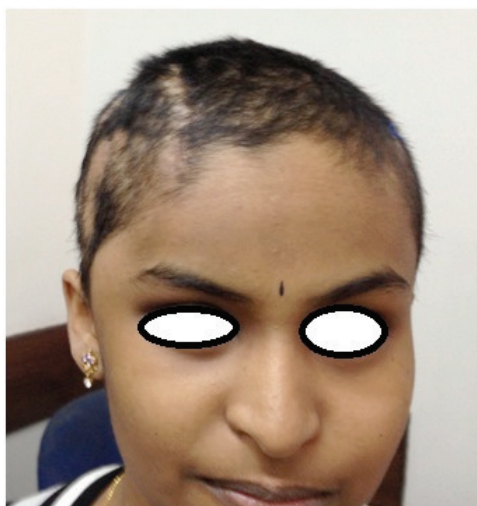

Figure 14: 6 weeks follow-up deformity corrected.



Figure 15: 18 months follow-up well concealed scars.

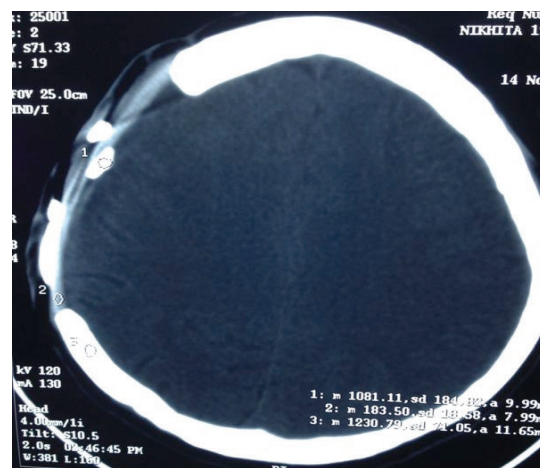


Figure 16: 18 months follow-up CT showing new bone formation over Osteomesh.

popularity. Further advances in alloplastic material gave wider variety for skull implants. Although many different methods had been described, there is still no consensus on which method is better (Table 1). The aim of cranioplasty is not only a cosmetic correction, the repair of cranial defects gives relief to psychologically and increases the social performances. Also the incidence of epilepsy is shown to be decreased after cranioplasty [2]. Contraindications for cranioplasty are the presence of hydrocephalus, infection, and brain swelling.

An ideal cranioplasty material must have the following features [3]:

- It must fit the cranial defect and achieve complete closure
- Radiolucency
- Resistance to infections
- Not dilated with heat
- Strong to biomechanical processes
- Easy to shape
- Not expensive
- Ready to use

Bone grafts have the advantage of being genetically identical and less prone to infection; they also preserve the protein matrix in which bone minerals remain stable and have fewer late resorption and other complications [4]. Other factors favoring the use of autogenous bone are no foreign body reaction, easy to contour grafts, and in some cases, such as the rib graft, the donor area shows signs of regeneration [5]. Nevertheless, the use of autogenous bone has its own drawbacks. The

Table 1:

Material	Advantage	Disadvantage
Outer table skull [8]	Easy to harvest	
Inner table Skull [9]	Less deformity and infection risk	Higher dural damage risk
Tibia [12]		Difficult harvesting Cranial contour not obtained
Ribs [13]		Complications like pneumothorax, chest deformities
Scapula		Difficulty harvesting prone position
Sternum [14]		High resorption rates
Ilium [15]	Similar contour	High complications hemorrhage bowel perforation nerve injuries high resorption rate
Autogenous Banked cranium [16]		Abdominal scarring, resorption
Allograft cadaveric cranium [17]		Infection, resorption
Xenograft scapula of cows and cranium of dogs [18]		Infection, resorption
Celluloid [19]		High rate of fluid collection and extrusion.
Methyl methacrylate [20]	Easy to shape, lighter in weight, radiates less heat, and radiolucent	Exothermic reaction brain damage, fracturing of implant, extrusion, infection, smooth surface characteristics that prevent tissue ingrowth
Hydroxyapatite [21]	Less tissue reaction, high osteointegration	High fracture rate
Silicone [22]	Less tissue reaction	Soft consistency
Polyethylene mesh [23]	Less tissue reaction Less prone to infection due to vascular ingrowth	Infection and exposure, non rigid.
Chorale [24]	Bone integration	Less durable
Alluminium [10] Silver Gold [1]		High infection rate Skin discoloration Expensive
Tantalum [25]		High cost Headaches, high heat conduction
Stainless steel titanium [26]	Less reactive Less infection	High exposure rate
Lead and platinum [27]	Easily mouldable	Lead toxicity High cost
Vitallium and ticonium [28]	Least corrosive Least tissue reaction	

harvesting procedure prolongs the operative time, the harvest area requires time to heal, and there is a limited supply of bone available. There are also other considerations, such as the increased surgical complexity, donor site morbidity, difficulty in giving shape to the graft, graft warpage, and resorption [6]. There is a correlation between the original size of the defect and the failure rates in skull grafting, defects larger than 75 cm² have a failure rate of around 60%, whereas those smaller than 75 cm² are associated with no failure.

The first case of bone transplantation was demonstrated by Söhr, in which he used only the external

tabula of cranium without periosteum [7,8]. Although the use of external tabula is a considerable way of cranioplasty, the use of internal tabula is rather new [9]. Split-thickness skull cranioplasty are biocompatible, which are easy to harvest and with less infection and deformity. For this reason, it is considered as a good option for cases with high risk of infection [10]. In pediatric patients with growing cranium, split-thickness skull grafts showed integration and cooperated with the remolding skull, in contrast to nonbiologic materials, which resulted in restricted growth of the skull and deformities [11].

An ideal osteogenic biomaterial should have the following characteristics (i) support the attachment and migration of osteoblasts throughout the biomaterial (i.e., be osteoconductive), (ii) induce the differentiation of osteoprogenitor cells into osteoblasts or promote osteoblast activity (i.e., be osteoinductive), and (iii) integrate with the newly formed bone and retaining similar mechanical properties as normal bone (i.e., exhibit osteointegration).

Using autogenous stem cells for bone regeneration is a promising technique as shown by Yamada *et al.* [29]. Mesenchymal stem cells derived from bone marrow had been used experimentally to increase bone regeneration. However, harvesting adult stem cells from bone marrow may only yield low numbers of stem cells [30]. Newer techniques of stem cells of stromal vascular fraction from adipose tissue by liposuction are easier alternatives.

3.1. Newer Materials

Bioglass 45S5 (SiO₂ 45 wt%, CaO 24.5 wt%, Na₂O 24.5 wt%, P₂O₅ 6 wt%) in granules form when mixed with dextran resembles putty that is easily moldable. Irregular and large bony defects can be filled with better stability, thus enhancing the handling characteristics of the material [31].

NovaBone (Porex Surgical, Inc), a synthetic particulate bioactive glass composed of 45% silicone dioxide, 45% sodium oxide, 5% calcium, and 5% phosphate, stimulate the production of the new bone by bioactive composites within the biomaterial [32].

Demineralized cortical bone matrix with microperforations can serve as the center for bone neoformation. Studies suggest that DBM maybe a reasonable alternative to autogenous bone [33]. DBM powder alone is placed in the defect thus preventing the ingrowth of undesirable soft tissue cells into an osseous defect. At the same time permitting the growth of osteogenic cells by using barrier membranes, enhances bone repair. This technique is known as guided bone regeneration [34]. Recently, a demineralized bone paste was made available commercially DBX Mineralized bone matrix 1 (Synthes Maxillofacial, Paoli, PA). Lactosorb (Lorenz Surgical, Jacksonville, FL) a bioresorbable polylactic/polyglycolic acid copolymer that has been used successfully for cranial vault reconstruction. The DBM and Lactosorb composite promoted complete bone bridging of a skull defect that was similar to the bone bridging seen with autogenous bone.

Porous β -TCP (Tricalcium phosphate) synthetic cancellous bone void fillers resemble human cancellous bone in structure and composition. β -TCPs contain approximately 39% calcium and 20% phosphorus by weight, similar to natural mineral content in bone. Vitoss is a porous, low-density construct prepared by lightly fusing particles of β -TCP that average approximately 1–2 μ m in diameter. Has been used as a bone filler in cranioplasty.

A composite graft can be defined as any combination of materials that includes an osteoconductive matrix, an osteogenic material, and an osteoinductive material, thus fulfilling the three requirements for a successful bone graft. Osteoconductive ceramic scaffold when seeded with bone progenitor cells from bone marrow, the composite graft would become osteogenic and osteoinductive as well, in effect providing a competitive alternative to autografts. Osteoprogenitor stem cells in bone marrow aspirate and are able to differentiate into five other cell types (osteoblasts, osteoclasts, adipose cells, chondroblasts, and fibroblasts) and modify their morphologic/functional attributes as needed [35].

Osteomesh is a bioresorbable implant of Polycaprolactone used in craniofacial surgery to repair various types of fractures, like the orbital floor fracture and in the augmentation or restoration of bony contour in the craniofacial skeleton to fill surgical defects. The shape is such that it conforms to the defect, thus maximizing direct contact with viable host bone. Its unique architecture allows rapid saturation with marrow, blood and nutrients, thus providing osseointegration and integration. Long-term clinical trials showed significant bone regeneration, as the material is slowly resorbed by the body and replaced by autologous bone [36,37].

3.2. Author's Surgical Tips for Osteomesh Cranioplasty

- Use Customised osteomesh implant with a titanium scaffold.
- Pre-surgical adequate scalp skin expansion with tissue expanders.
- Skin incision should be placed far away from mesh-bone junction.
- Freshening of the free bone edges and making a groove between outer and inner table for proper fit of osteomesh.
- Soaking the osteomesh flap in bone marrow stem cell rich fluid or with platelet rich plasma.

- Adequate and snug contact of flap with bone.
- Anchoring of scaffold with screws to prevent micro-motion.
- Complete covering of osteomesh with pedicled pericranial flap.
- Lax skin closure with drain.

4. CONCLUSION

Surgical repair of large calvarial defects still remains a controversy, regarding the ideal implant material and timing to surgery. The ideal implant material should be inexpensive, readily available in sufficient quantities, biocompatible, easy to contour, provide rigid support and free of any systemic effects. In our study, favourable properties of PCL as an osteomesh with a titanium scaffold are translated into its use for reconstruction of the calvaria. The application of stem cell therapy potentiated with bone morphogenic protein (BMP) for osseointegration has proven to be effective. A complete pericranial cover achieved by prior scalp expansion aided in vascularity for bone growth. Anchoring of scaffold with screws achieved snug contact of flap with bone, preventing even micro-motion. The various surgical techniques applied in this case helped in achieving good aesthetic results hence giving an example of customization in the field of cranioplasty.

REFERENCES

- [1] Sanan A, Haines SJ. Repairing holes in the head: A history of cranioplasty. *Neurosurgery* 1997; 40: 588-603.
- [2] Aydin S, Kucukyuruk B, Abuzayed B, Aydin S, Sanus GZ. Cranioplasty: Review of materials and techniques. *J Neurosci Rural Pract.* 2011; 2(2): 162-167.
<http://dx.doi.org/10.4103/0976-3147.83584>
- [3] Blake DP. The use of synthetics in cranioplasty: A clinical review. *Mil Med.* 1994; 159: 466-9.
- [4] Moreira-Gonzalez A, Jackson IT, Miyawaki T, Barakat K, DiNick V. Clinical outcome in cranioplasty: critical review in long-term follow-up. *J Craniofac Surg.* 2003; 14: 144-153.
<http://dx.doi.org/10.1097/00001665-200303000-00003>
- [5] Beekmans SJ, Don Griot JP, Mulder JW. Split rib cranioplasty for aplasia cutis congenita and traumatic skull defects: more than 30 years of follow-up. *J Craniofac Surg.* 2007; 18: 594-7.
<http://dx.doi.org/10.1097/scs.0b013e3180576f44>
- [6] Frodel JL, Lee S. The use of high-density polyethylene implants in facial deformities. *Arch Otolaryngol Head Neck Surg.* 1998; 124: 1219-1223.
<http://dx.doi.org/10.1001/archotol.124.11.1219>
- [7] Prolo DJ, Burres KP, McLaughlin WT, Christensen AH. Autogenous skull cranioplasty: Fresh and preserved (frozen), with consideration of the cellular response. *Neurosurgery* 1979; 4: 18-29.
<http://dx.doi.org/10.1227/00006123-197901000-00005>
- [8] Viterbo F, Palhares A, Modenese E. Cranioplasty: The autograft option. *J Craniofac Surg.* 1995; 6: 80-3.
<http://dx.doi.org/10.1097/00001665-199501000-00019>
- [9] Zins JE, Langevin CJ, Nasir S. Controversies in skull reconstruction. *J Craniofac Surg.* 1998; 15: 20-26.
- [10] Black SP. Reconstruction of the supraorbital ridge using aluminum. *Surg Neurol.* 1978; 9: 121-8.
- [11] Abuzayed B, Tuzgen S, Canbaz B, Yuksel O, Tutunculer B, Sanus GZ. Reconstruction of growing skull fracture with in situ galeal graft duraplasty and porous polyethylene sheet. *J Craniofac Surg.* 2009; 20: 1245-9.
<http://dx.doi.org/10.1097/SCS.0b013e3181acdfaf>
- [12] Hadley FA. Skull defects repaired by tibial grafts. *J. Col Surg Australia I* 1924; 208: 1928-1929.
- [13] Taggard DA, Menezes AH. Successful use of rib grafts for cranioplasty in children. *Pediatr Neurosurg.* 2001; 34: 149-55.
<http://dx.doi.org/10.1159/000056010>
- [14] Westermann CWJ. Zur Methodik der Deckung von Schadeldefekten. *Zentralbl F Chir.* 1916; 43: 113.
- [15] Dingman RO. Iliac bone cranioplasty. *Plast Reconstr Surg.* 1952; 9(2): 130-9.
<http://dx.doi.org/10.1097/00006534-195202000-00007>
- [16] Shoakazemi A, Flannery T, McConnell RS. Long-term outcome of subcutaneously preserved autologous cranioplasty. *Neurosurgery* 2009; 65: 505-510.
<http://dx.doi.org/10.1227/01.NEU.0000350870.69891.86>
- [17] Pankratiev BE. Dead bone grafts to repair skull defects. *Ann Surg.* 1933; 97(3): 321-326.
<http://dx.doi.org/10.1097/00000658-193303000-00001>
- [18] Grant FC, Norcross NC. Repair of cranial defects by cranioplasty. *Ann Surg.* 1939; 110(4): 488-512.
<http://dx.doi.org/10.1097/00000658-193910000-00002>
- [19] Frey V. Tyber Einheilung von Celluloidplatten. *Wein Klin Wchnischr.* 1894; 7: 40.
- [20] Alexander VG. Preformed polymethylmethacrylate cranioplasties. *J Max-Fac Surg.* 1985; 13: 2-8.
[http://dx.doi.org/10.1016/S0301-0503\(85\)80005-9](http://dx.doi.org/10.1016/S0301-0503(85)80005-9)
- [21] Gosain AK. Hydroxyapatite cement paste cranioplasty for the treatment of temporal hollowing after cranial vault remodeling in a growing child. *J Craniofac Surg.* 1997; 8: 506-11.
<http://dx.doi.org/10.1097/00001665-199711000-00017>
- [22] Chicarilli ZN, Ariyan S. Cranioplasty with a silicone prosthesis and split rib grafts. *Head Neck Surg.* 1986; 8: 355-62.
<http://dx.doi.org/10.1002/hed.2890080506>
- [23] Liu JK, Gottfried ON, Cole CD, Dougherty W, Couldwell WT. Porous polyethylene implant for cranioplasty and skullbase reconstruction. *Neurosurg Focus* 2004; 16: ECP1.
- [24] Arnaud E, De Pollak C, Meunier A, Sedel L, Damien C, Petite H. Osteogenesis with coral is increased by BMP and BMC in a rat cranioplasty. *Biomaterials* 1999; 20: 1909-18.
[http://dx.doi.org/10.1016/S0142-9612\(99\)00090-3](http://dx.doi.org/10.1016/S0142-9612(99)00090-3)
- [25] Makela T. Tantalum cranioplasty of war wounds of the skull. *Ann Chir Gynaecol Fenn.* 1949; 38: 13-9.
- [26] Kuttenger JJ, Hardt N. Long-term results following reconstruction of craniofacial defects with titanium micro-mesh systems. *J Craniomaxillofac Surg.* 2001; 29: 75-81.
<http://dx.doi.org/10.1054/jcms.2001.0197>
- [27] Chen J, Qian C, Xie Y. Clinical analysis of 21 cases autologous skull fragments plasty in situ using platinum connector added medical glue. *Modern Hospital* 2009; 11: 020.

- [28] Campbell E, Meirowsky A, Tompkins V. Studies on the use of metals in surgery- part II: Experiments on the use of Ticonium in cranial repair. *Annal Surg.* 1942; 116(5): 763.
<http://dx.doi.org/10.1097/0000658-194211650-00012>
- [29] Yamada Y, Boo JS, Ozawa R, Nagasaka T, Okazaki Y, Hata Ki, *et al.* Bone regeneration following injection of mesenchymal stem cells and fibrin glue with a biodegradable scaffold. *J Craniomaxillofac Surg.* 2003; 31(1): 27-33.
[http://dx.doi.org/10.1016/S1010-5182\(02\)00143-9](http://dx.doi.org/10.1016/S1010-5182(02)00143-9)
- [30] Haynesworth SE, Goshima J, Goldberg VM, Caplan AI. Characterization of cells with osteogenic potential from human marrow. *Bone* 1992; 13: 81-88.
[http://dx.doi.org/10.1016/8756-3282\(92\)90364-3](http://dx.doi.org/10.1016/8756-3282(92)90364-3)
- [31] Chan C, Thompson I, Robinson P, Wilson J, Hench L. Evaluation of bioglass/dextran composite as a bone graft substitute. *Int J Oral Maxillofac Surg.* 2002; 31: 73-77.
<http://dx.doi.org/10.1054/ijom.2001.0143>
- [32] Gosain AK. Plastic Surgery Educational Foundation DATA Committee. Biomaterials for reconstruction of the cranial vault. *Plast Reconstr Surg.* 2005; 116: 663-666.
<http://dx.doi.org/10.1097/01.prs.0000176289.05374.5b>
- [33] Salyer KE, Bardach J, Squier CA, Gendler E, Kelly KM. Cranioplasty in the growing canine skull using demineralized perforated bone. *Plast Reconstr Surg.* 1995; 96: 770-779.
<http://dx.doi.org/10.1097/00006534-199509001-00002>
- [34] Clokie CM, Moghadam H, Jackson MT, Sandor GKB. Closure of critical size defects with allogeneic and alloplastic bone substitutes. *J Craniofac Surg.* 2002; 13: 111-121.
<http://dx.doi.org/10.1097/00001665-200201000-00026>
- [35] Erbe E, Marx J, Clineff T, Bellincampi L. Potential of an ultra-porous β -tricalcium phosphate synthetic cancellous bone void filler and bone marrow aspirate composite graft. *Eur Spine J.* 2001; 10(2): S141-6.
- [36] Chen TM, Tsai JC, Burnouf T. Cranioplasty using osteoconductive polycaprolactone (PCL) (OsteoMesh[®], Osteopore, Singapore) scaffold and platelet glue. *J Trauma Acute Care Surg.* 2008; 65(6): 1321-7.
<http://dx.doi.org/10.1097/TA.0b013e3181574edf>
- [37] Low SW, Ng YJ, Yeo TT, Chou N. Use of OsteoplugTM polycaprolactone implants as novel burr-hole covers Singapore. *Med J.* 2009; 50(8): 777.

Received on 15-02-2016

Accepted on 03-03-2016

Published on 10-03-2016

© 2016 Yogishwarappa *et al.*; Licensee Synchro Publisher.

This is an open access article licensed under the terms of the Creative Commons Attribution Non-Commercial License (<http://creativecommons.org/licenses/by-nc/3.0/>), which permits unrestricted, non-commercial use, distribution and reproduction in any medium, provided the work is properly cited.