

# Heminasal Aplasia, a Rare Congenital Anomaly of Nose: Case Report and Review of Management Strategies

S.S. Shirol<sup>1,\*</sup>, Jaideep Ratkal<sup>2</sup>, Prajna Salian<sup>3</sup>, N. Shankar<sup>4</sup>, Ritam Dessai<sup>4</sup>, Mahesh Prabhu<sup>5</sup>, Arun Walwekar<sup>4</sup> and K. Aravind<sup>6</sup>

<sup>1</sup>Sampige Cosmetic & Plastic Surgery Clinic, Hubli and Department of Plastic Surgery, KIMS, Vidyanagar, Hubli 580032, Karnataka, India; <sup>2</sup>Department of Urology, KIMS Hubli, <sup>3</sup>Department of ENT, KIMS Hubli, <sup>4</sup>Department of General Surgery, KIMS Hubli, <sup>5</sup>Department of Plastic Surgery, KLE University, Belgaum and <sup>6</sup>Sampige Cosmetic & Plastic Surgery Clinic, Hubli, India

**Abstract:** Heminasal aplasia is a rare congenital anomaly of nose that has rarely been reported in the English literature. The surgical management remains a challenge due to its rarity and lack of uniform management guidelines. We report a case of heminasal aplasia, managed successfully at our institute and systematic review of the available literature.

**Keywords:** Heminasal aplasia, Hemi-arhinia, Aplasia nose, Arhinia, Absent nose, Half nose, Reconstruction, Anomaly of nose, Nasolabial flap, Folded nasolabial flap.

## 1. INTRODUCTION

Congenital absence of either one half (Hemi-arhinia) or the whole nose (Arhinia), is a rare congenital anomaly. Due to its rarity, scant reportage and lack of uniform reconstructive protocols about the surgical technique and timing of repair, surgical management remains a challenge to the plastic surgeon. The anomaly, its association with other synchronous anomalies of the face and multiple stages of reconstruction add financial burden to the existent social stigma of the patient and the parents. The goals of nasal reconstruction include restoration nasal airway and aesthetically pleasing nose. In this paper we report a case of heminasal aplasia in an adolescent, reconstruction done using superiorly based nasolabial flap and reviewed the existing English literature.

## 2. CASE REPORT

A 12 year old girl presented to us with the complete absence of left side of nose (Figure 1a-c), with no difficulty in breathing. The peer pressure at school and stigma of a 'Half- Nose' forced the child to miss the school and forced the anxious parents to seek reconstruction of nose. Oto-rhino laryngological examination was unremarkable. 3-Dimensional C.T scan revealed heminose, absence of any other anomalies in the face. The reconstruction of the nasal ala, (both the cover and lining) was achieved by a superiorly based folded naso-

labial flap without the cartilage framework reconstruction. The flap donor site was closed primarily by extensive undermining and cheek advancement. The nasal cavity was packed with antibiotic impregnated gauze, removed on second post-operative day. The post-operative period was uneventful. Though the patient was using silicone conformer for six months to prevent nostril stenosis, there was some stenosis and asymmetry of nasal ala with stretching of the scar (Figure 2a-c). The parents were advised revision and correction of the asymmetry with conchal cartilage but refused further intervention, being satisfied with relative improvement in nasal aesthetics and inability to bear additional financial burden.

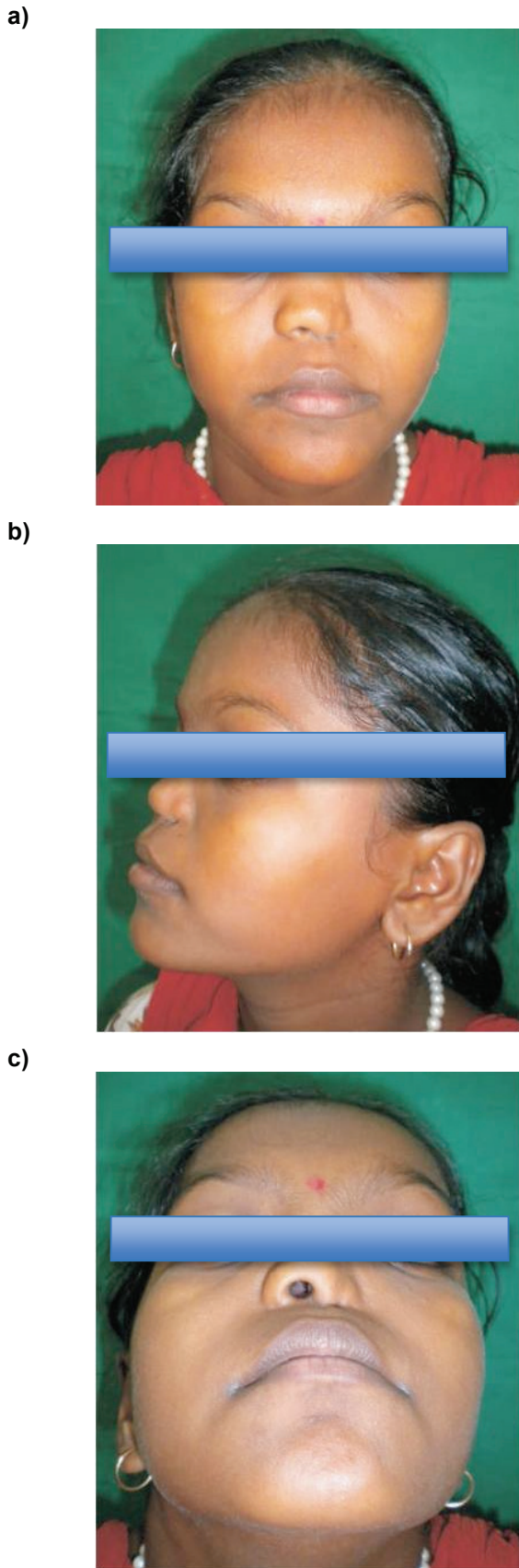
## 3. DISCUSSION AND REVIEW OF LITERATURE

Heminasal aplasia, hemi-arhinia or unilateral aplasia of the nose is a rare congenital malformation (91 cases reported till 2008) [1] with absence of half of the external nose together with a variable degree of abnormality of internal anatomy of the nose and adjacent facial structures. The anomaly imposes a huge psychological impact on the family due to social stigma attached to it. The anomaly has other associated malformations of the facial region, like ophthalmic, lachrymal system; Nasal & maxillary bone anomalies and most commonly, proboscis lateralis.

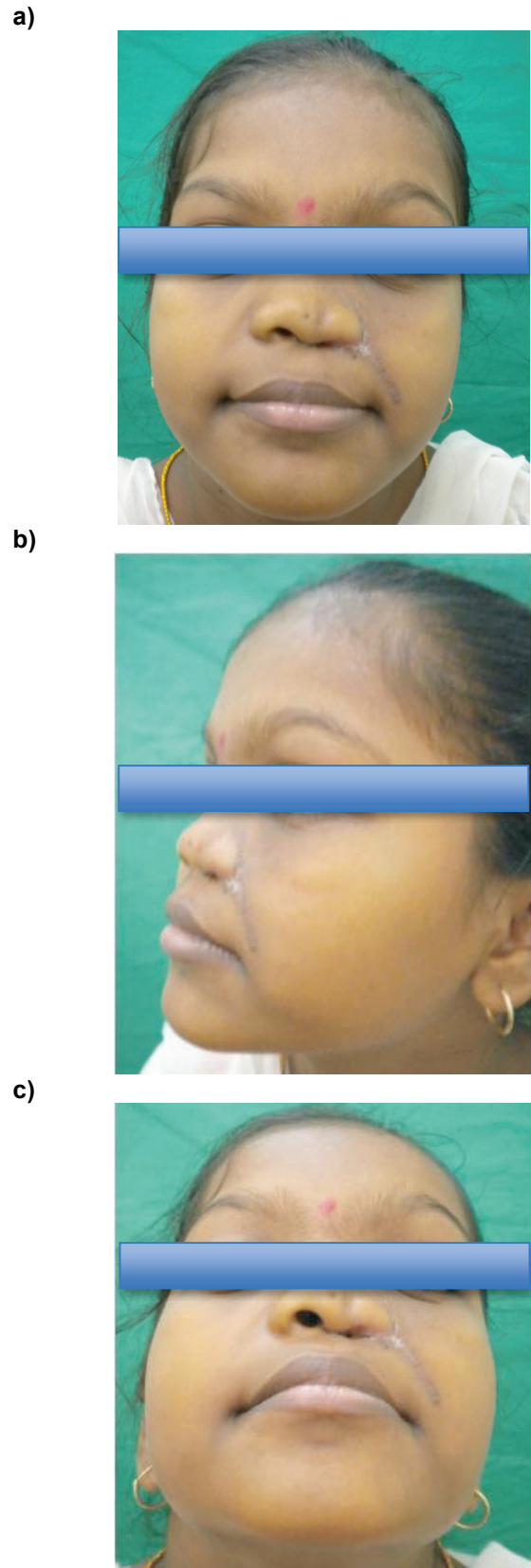
### 3.1. Embryology

The nose develops from the mesodermal derivatives, fronto-nasal process and the two nasal placodes during third to seventh week of intrauterine life. A central invagination, called the nasal pit, divides each

\*Address correspondence to this author at the Sampige Super-Specialty Clinic, Hubli and Department of Plastic Surgery, KIMS, Vidyanagar, Hubli 580032, Karnataka, India; Tel: 91-94801 89228, 91-73537 56777; E-mail: ssshiorol@yahoo.co.uk



**Figure 1:** Pre-operative photographs. (a) front view showing the absent left nasal ala; (b) Oblique view –normal dorsum of nose; (c) Worms' eye view with absence of left nasal cavity.



**Figure 2:** Post-operative photographs. (a) Post-operative front view-stretched scar at the flap donor site and good width of nasal ala; (b) Oblique view – reasonably good contour of ala; (c) Worms' eye view – inadequate height of ala and constricted nostril.

nasal placode into a medial and a lateral nasal process and extending posteriorly to form the nasal cavity, being separated from the oral cavity by a thin naso-buccal membrane. The naso-buccal membrane ruptures eventually, during sixth week to form the posterior choanae. The specialized olfactory sensory cells develop as the epithelium around the forebrain thickens. The medial nasal processes from both sides fuse and form the nasal septum and philtrum while the lateral processes develop into the external wall of the nose, the nasal bones, the upper lateral cartilages, the alae, and the lateral crura of the lower lateral cartilages. The failure of the development of nasal placodes probably leads to the congenital absence of nose [2].

Several theories have been advanced to understand this rare anomaly. These include 1) failure of the medial and lateral nasal processes to grow; 2) premature fusion of the medial nasal processes; 3) lack of resorption of the nasal epithelial plug; and 4) abnormal migration of the neural crest cells [3,4]. Congenital arhinia may in part be induced by chromosomal aberrations reported in the literature. The genetic aberrations reported in association with arhinia were - 19 Mb large deletion involving 3q11-q13 [5]; translocation between chromosomes 3 and 12 [6]; inversion of chromosome 9 and mosaic of chromosome 9 [7].

Failure of development of both nasal placodes results in complete nasal aplasia or arhinia while that of one placode leads to heminasal aplasia or hemi-arhinia [8]. Nasal anomalies rarely occur alone and are frequently associated with other coexistent craniofacial anomalies. They are classified into two major groups: 1. total arhinia, with absence of the nose and both olfactory nerves; 2. partial arhinia with presence of at least one nostril and one olfactory tract. Both groups may or may not be associated with other craniofacial malformations [7]. Presentation of partial arhinia ranges from hypoplasia or absence of only an individual structure to a complete absence of the heminose. Naso-lacrimal system develops into the nasal maxillary groove, but in half-nose cases it is blind. During facial development, maxilla generally has a growth deficiency in both sagittal and vertical dimensions and results in malocclusion [8].

### 3.2. Management

The management of arhinia is a surgical challenge as there is no consensus regarding the timing and technique of reconstruction. The goals of total nasal

reconstruction include restoration nasal airway and aesthetically pleasing nose. The ability to breathe, the adequacy of the air passages and the cosmetic appearance determine the timing of surgery. Both from the cosmetic and psychological point of view, early childhood interventions are thought to be better [9]. Onizuka et al. began their reconstructive surgery in their case of arhinia at the age of 6 months, completed reconstruction at 18 months of age [10], and recommend early operative correction to achieve a better morphology in the absence of cerebral anomaly. Muhlbauer et al. started their reconstruction of both the internal and external nose at 4 months, completing at 26 months [11]. Few authors recommend that the surgical reconstruction of the nose and its internal cavities be delayed at least until preschool years [7,12-15], while others postpone the nasal reconstruction till the age of 15 years when facial development is nearly complete [16].

When present the proboscis is the best tissue for nasal reconstruction; but, in its absence forehead flap is a good alternative for the nose reconstruction. To achieve symmetry and contour, further procedures including insertion of bone graft, z-plasty and debulking may be needed [17].

Full-thickness nasal defects require reconstruction of the lining, support and external coverage [18]. Burget and Menick [19] have proposed nine subunits for nasal repair, while Giugliano [20] divided the nose into three aesthetic units: tip, dorsum and ala. These principles of units and subunits should be considered while reconstruction hemi-nose defects too. There are few options to reconstruct external coverage of the nose, including local flaps, forehead flaps, forearm free flaps and also tissues of the proboscis lateralis. Forehead expansion creates a large capsule, which can contract in postoperative period, leading to a short nose on long-term result. The pedicle may be designed contralateral or ipsilateral to the primary nasal defect. Historically, contralateral design has been preferred because it results in less torsion on the pedicle [21]. A thinner flap may improve the pliability of the flap with better nasal contour. A third-stage procedure aiming to thin the flap and revise the scars should be performed about 6 months later when wound healing and scar contractures are definitive.

Local flaps such as contralateral cutaneous nasal flap, nasolabial flaps, nasal or septal mucosal flaps are feasible options to reconstruct the inner lining. Bhandari et al. [22] demonstrated the use of a nasolabial flap for



nasal lining. Other authors have published the use of skin graft or oral mucosal flap [23]. Nasal airway lined by split-skin graft, however, tends to have stenosis, needing splints or silicone stents to prevent. Nasal framework reconstruction has been described using conchal cartilage, costal cartilage, and rib and calvarium bone grafts [24].

In our opinion reconstruction of congenital half-nose is more challenging as there is already an existing half nose, which is normal and the reconstruction has to match the normal side, even though there is more donor site available for lesser tissue requirement for reconstruction. We feel that, the superiorly based nasolabial flap should be primary choice in reconstructing hemi-arhinia as it is a single staged procedure, and preserves forehead flap for possible future use, if any secondary reconstruction is required. Hemi-arhinia has additional challenge, as in total arhinia, the restoration of nasal airway. Its reconstruction in the same stage is even more difficult and has scarcely been reported in the literature [22]. Moreover, reconstructed airway tends to become stenotic, and measures must be taken to minimise tissue contraction. Nagase stated that nasal airway reconstruction might not be required in congenital hemi-nose, because these patients usually do not have problems in breathing when they have the contralateral nasal airway intact [24].

#### 4. CONCLUSION

Heminasal aplasia, a rare congenital anomaly of nose poses a major challenge for reconstructive surgeons due to lack of uniform reconstructive protocols. We strongly feel that folded nasolabial flap be considered as a primary choice of reconstruction of these anomalies. As this is a single staged procedure and preserves forehead for a possible future use.

#### REFERENCES

[1] da Silva Freitas R, Alonso N, de Freitas Azzolini T, Busato L, Tolazzi AR, e Cruz GA, *et al*. The surgical repair of half-nose. *J Plast Reconstr Aesthet Surg*. 2010; 63(1): 15-21. <http://dx.doi.org/10.1016/j.bjps.2008.08.040>

[2] Nishimura Y. Embryological study of nasal cavity development in human embryos with reference to congenital nostril atresia. *Cells Tissues Org*. 1993; 147(3): 140-4. <http://dx.doi.org/10.1159/000147494>

[3] Albernaz VS, Castillo M, Mukherji SK, Ihmeidan IH. Congenital arhinia. *AJNR Am J Neuroradiol*. 1996; 17(7): 1312-4.

[4] Mathur NN, Dubey NK, Kumar S, Bothra R, Chadha A. Arhinia. *Int J Pediatr Otorhinolaryngol*. 2005; 69: 97-99. <http://dx.doi.org/10.1016/j.ijporl.2004.07.016>

[5] Sato D, Shimokawa O, Harada N, Olsen OE, Hou JW, Muhlbauer W, *et al*. Congenital arhinia: molecular-genetic

analysis of five patients. *Am J Med Genet A*. 2007; 143(6): 546-52. <http://dx.doi.org/10.1002/ajmg.a.31613>

[6] Hou JW. Congenital arhinia with de novo reciprocal translocation, t(3;12)(q13.2;p11.2). *Am J Med Genet A*. 2004; 130A(2): 200-3. <http://dx.doi.org/10.1002/ajmg.a.30268>

[7] Cohen D, Goitein KJ. Arhinia revisited. *Rhinology* 1987; 25(4): 237-44.

[8] Motohashi N, Kuroda T, Cohen Jr MM. Eye and ear anomalies and facial asymmetry: report of a case analysis and orthodontic treatment. *Cleft Palate Craniofac J*. 1999; 36: 353. [http://dx.doi.org/10.1597/1545-1569\(1999\)036<0353:HNWIEA>2.3.CO;2](http://dx.doi.org/10.1597/1545-1569(1999)036<0353:HNWIEA>2.3.CO;2)

[9] Rontal M, Duritz G. Proboscis lateralis: case report and embryologic analysis. *Laryngoscope* 1977; 87(6): 996-1006. <http://dx.doi.org/10.1288/00005537-197706000-00017>

[10] Onizuka P, Ohkubo F, Hosaka Y, Ichinose M, Keiko Okazaki K. Arhinia: A case report. *Worldplast*. 1995; 1: 65-71.

[11] Muhlbauer W, Schmidt A, Fairley J. Simultaneous construction of an internal and external nose in an infant with arhinia. *Plast Reconstr Surg*. 1993; 91(4): 720-5. <http://dx.doi.org/10.1097/00006534-199304000-00027>

[12] Weinberg A, Neuman A, Benmeir P, Lusthaus S, Wexler MR. A rare case of arhinia with severe airway obstruction: case report and review of the literature. *Plast Reconstr Surg*. 1993; 91(1): 146-9. <http://dx.doi.org/10.1097/00006534-199301000-00024>

[13] Cole RR, Myer CM 3rd, Bratcher GO. Congenital absence of the nose: a case report. *Int J Pediatr Otorhinolaryngol*. 1989; 17(2): 171-7. [http://dx.doi.org/10.1016/0165-5876\(89\)90092-X](http://dx.doi.org/10.1016/0165-5876(89)90092-X)

[14] Meyer R. Total external and internal construction in arhinia. *Plast Reconstr Surg*. 1997; 99(2): 534-42. <http://dx.doi.org/10.1097/00006534-199702000-00036>

[15] McGlone L. Congenital arhinia. *J Paediatr Child Health* 2003; 39(6): 474-6. <http://dx.doi.org/10.1046/j.1440-1754.2003.00193.x>

[16] Navarro-Vila C, Matias GC, Martinez GC, Verdaguier MJ, Acero SJ, Perez SV, *et al*. Congenital absence of the nose and nasal fossae. *J Craniomaxillofac Surg*. 1991; 19(2): 56-60. [http://dx.doi.org/10.1016/S1010-5182\(05\)80607-9](http://dx.doi.org/10.1016/S1010-5182(05)80607-9)

[17] Kingsly P, Prema D, Ashish KG, Sunil B. Heminasal Aplasia : A report of two cases. *Indian J Otolaryngol Head Neck Surg*. 2007; 59(1): 58-9. <http://dx.doi.org/10.1007/s12070-007-0017-2>

[18] Millard DR Jr. Hemirhinoplasty. *Plast Reconstr Surg*. 1967; 40: 440-445. <http://dx.doi.org/10.1097/00006534-196711000-00003>

[19] Burget GC, Menick FJ. *Aesthetic Reconstruction of the Nose*. St Louis, Mo: Mosby-Year Book Inc. 1994; 57-91.

[20] Giugliano C, Andrades PR, Benitez S. Nasal reconstruction with a forehead flap in children younger than 10 years of age. *Plast Reconstr Surg*. 2004; 114: 316-25. <http://dx.doi.org/10.1097/01.PRS.0000131870.52649.98>

[21] Boyd CM, Baker SR, Fader DJ, Wang TS, Johnson TM. The forehead flap for nasal reconstruction. *Arch Dermatol*. 2000; 136: 1365. <http://dx.doi.org/10.1001/archderm.136.11.1365>

[22] Bhandari PS. Simultaneous and symmetrical reconstruction of heminose and restoration of nasal airway in congenital absence of heminose. *Br J Plast Surg*. 2004; 57: 575-578. <http://dx.doi.org/10.1016/j.bjps.2004.01.007>

- [23] Cotin G, Bodard M, Bouchenak B, Garabedian N. Reconstruction de l'orifice et du vestibule narinaire dans le proboscis lateralis. *Ann Chir Plast.* 1982; 27: 144.
- [24] Nagase T, Kobayashi S, Ohmori K. Achieving natural shading of the nostril in the reconstruction of a half nose. *Br J Plast Surg.* 1998; 51: 131-134.  
<http://dx.doi.org/10.1054/bjps.1997.0152>

---

Received on 05-12-2015

Accepted on 01-01-2016

Published on 19-02-2016

© 2016 Shirol *et al.*; Licensee Synchro Publisher.

This is an open access article licensed under the terms of the Creative Commons Attribution Non-Commercial License (<http://creativecommons.org/licenses/by-nc/3.0/>), which permits unrestricted, non-commercial use, distribution and reproduction in any medium, provided the work is properly cited.