

Ovarian Fibroma Ossification: A Common Tumor with an uncommon Feature

Vasileiadou Dimitra^{1,*}, Papamargaritis Eythimios¹, Apessou Dimitra² and Sofoudis Chrisostomos¹

¹Department of Obstetrics & Gynecology, Konstantopouleio General Hospital of Nea Ionia, Athens, 14233, Greece

²Department of Pathology, Konstantopouleio General Hospital of Nea Ionia, Athens, 14233, Greece

Abstract: Ovarian thecoma-fibroma groups (OTFG) are uncommon sex cord-stromal neoplasms. Most of them are benign, and often found in postmenopausal patients. *Thecomas* are less common than granulosa cell tumors, but they have similar appearances. They are solid fibromatous lesions that show varying degrees of yellow or orange coloration. According to current bibliography, cases of ovarian fibromas with further ossification, are extremely rare entities. Objective of our study, consists of presentation of such rare case, properly diagnosed and treated followed by depiction of its pathogenic mechanisms.

Keywords: Ovarian fibroma, Ossification, Thecoma.

INTRODUCTION

Ovarian fibromas belong to the sex cord – stromal group of ovarian tumors (SCSTs). They are the most common benign, solid neoplasms of the ovary. They make up approximately 5% of benign ovarian neoplasms and approximately 20% of all solid tumors of the ovary. Their malignant potential is low, less than 1%. [1]

They vary in size from small nodules to huge pelvic tumors, yet their average diameter is six centimeters. One of their predominant features is that they are extremely slow growing. Ninety percent of fibromas are unilateral, however, multiple fibromas are found in the same ovary in 10% to 15% of cases.[1]

The average age at presentation is 48 years, therefore this tumor often presents in postmenopausal women. The symptoms that arise with growth of fibromas include pressure and abdominal enlargement, which may be due to the size of the tumor itself or the extent of ascites, which often accompanies ovarian fibromas; smaller tumors are often asymptomatic. Many ovarian fibromas are misdiagnosed and believed to be leiomyomas prior to surgery.[1]

Meigs' syndrome represents the association of an ovarian fibroma, ascites and hydrothorax. Both ascites and hydrothorax resolve after removal of the ovarian tumor. The ascites is caused by transudation of fluid from the ovarian fibroma and the incidence of ascites is related to the size of the fibroma. Fifty percent of patients have ascites if the fibroma is larger than six centimeters, however true Meigs' syndrome is rare, occurring in less than 2% of ovarian fibromas. The right pleural space is involved in 75% of reported cases, the left in 10% and both sides in 15%. The clinical features of

Meigs' syndrome are not unique to fibromas and a similar clinical picture is found with many other ovarian tumors.[1]

Histologically, fibromas are composed of connective tissue, stromal cells, and varying amounts of collagen. The connective tissue cells are spindle-shaped, mature fibroblasts. It is sometimes difficult to distinguish fibromas from *nonneoplastic thecomas*. Management of fibromas is straightforward because any woman with a solid ovarian neoplasm should have an exploratory operation soon after the tumor is discovered. Simple excision of the tumor is all that is necessary. Because these tumors are frequently discovered in postmenopausal women, often a bilateral salpingo-oophorectomy and total abdominal hysterectomy are performed.[1]

CASE

A 73-year-old patient (G2P2), attended at our Department complaining episodes of severe abdominal pain. Pap smear revealed no signs of malignancy.

Physical examination described tenderness around peritoneal cavity.

Transvaginal ultrasound revealed presence of tumor maximal diameter 9cm located in the anatomic region of right ovary. Tumor markers free of malignancy.

Upper and down abdominal CT confirmed all preoperative imaging findings.

Patient underwent exploratory laparotomy, followed by frozen section of right adnexa. (*Figure 1.*)

A frozen section was sent to Pathology, which was diagnostic of a mesenchymal neoplasm with no cell atypia and suggested a differential between a leiomyoma and an *ovarian fibroma – thecoma*.

*Address correspondence to this author at the Department of Obstetrics & Gynecology, Konstantopouleio General Hospital of Nea Ionia, Athens, 14233, Greece; Email: chrisostomos.sofoudis@gmail.com

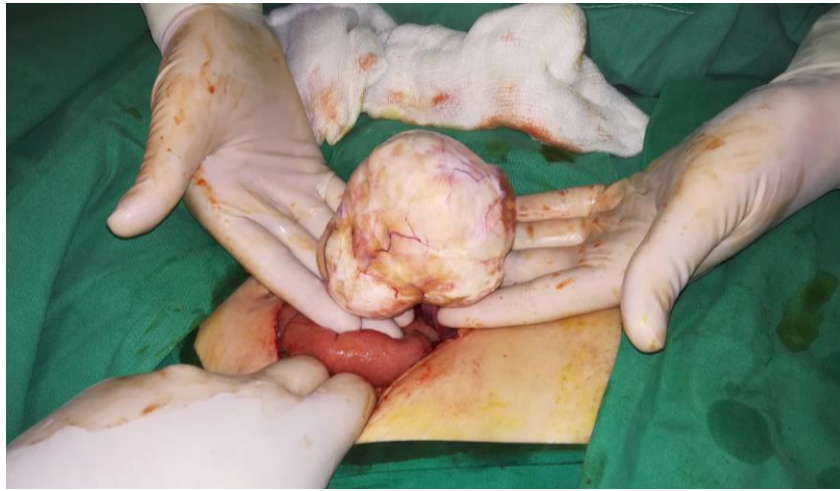


Figure 1: Ovarian fibroma ossification.

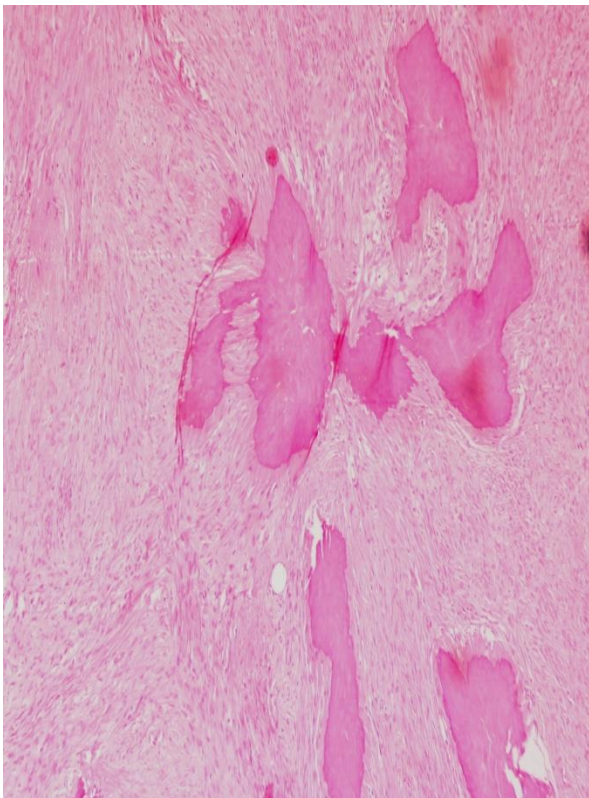


Figure 1: Ovarian fibroma ossification. H&E X100.

After the exclusion of malignancy, patient underwent total abdominal hysterectomy with bilateral salpingo-oophorectomy.

Cytological evaluation of peritoneal fluid did not reveal signs of malignancy.

Patient had an uneventful intra- and post-operative course and was discharged on postoperative day 4.

Final histopathology report described a white solid neoplastic tumor 9 x 6.5 x 5.5 cm in dimensions, with a smooth surface. The cut surface had a *trabeculated* appearance and an elastic consistency.

Microscopically, tumor consisted of medium cellularity and consisted of spindle – shaped cells in bundles, without nuclear atypia or mitoses. The tumor has edematous areas and extensive ossification, presenting as multiple, small, diffuse deposits of lamellar bone tissue. In a few peripheral sites, ovarian cortex was recognized (stroma and corpora albicantia). (Figures II, III.)

Immunohistochemical analysis of the neoplastic tumor was: SMA focally mildly positive, calponin focally mildly positive, calretinin focally positive, desmin negative, caldesmon negative, α -inhibin negative, CD10 negative and ER negative.

Conclusive diagnosis described an ovarian fibroma with ossification.

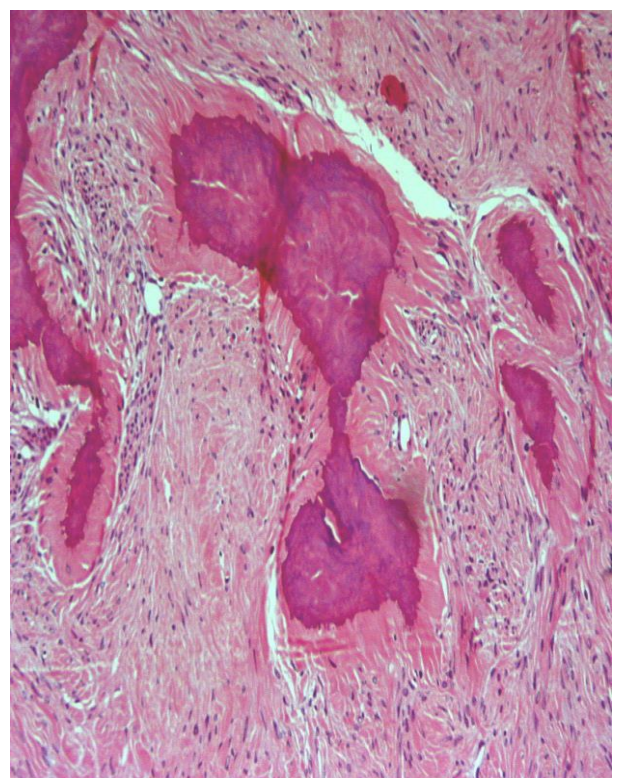


Figure 2: Ovarian fibroma ossification. H&E X200.

DISCUSSION

Ossification can occur anywhere in the soft tissue and is a well-recognized entity. *Etiologies include trauma, chronic inflammation, nonabsorbed hematoma, tumors, hypercalcemia, and hypervitaminosis.* [2] Bone formation in the ovary, with the exception of developing in the setting of a mature cystic teratoma or a heterologous mixed mesodermal tumor, is quite uncommon. To our knowledge, few literature reports exist on ovarian tumors with ossification.

Osseous metaplasia in the ovary has been described in cases of mucinous cystadenoma [3-6], cystadenocarcinoma [7-9], endometriosis [10], Sertoli Leydig cell tumor [11], in association with a cloacal anomaly [12] or a supernumerary ovary [13] and, finally, in an isolated form, not accompanied by other concomitant ovarian pathologic entities. [14]

Moreover, cases of ossification in thecomas (which sometimes share features with fibromas, giving rise to the term fibrothecoma) have been reported [15-17], among which a case associated with endometrial adenocarcinoma.[16] Ossification in fibromas has been previously reported [18, 19], including a case of a paraovarian fibroma [20] and a case of fibromas in a patient with Sotos syndrome. [21]

In the female genital tract, osseous metaplasia has been described in the vagina, endometrium (causing subfertility) [22-25] and cervix [26, 27], as well as a case of simultaneous ovarian and endometrial osseous metaplasia. [28]

The cause for bone formation in the ovary is not known. A previous torsion or infarction can explain the bone formation seen in some non-neoplastic lesions of the ovary like endometriotic cyst and in normal ovaries.

Most plausible explanation for bone formation in an ovarian neoplasm is hyalinization, dystrophic calcification and osseous metaplasia.[29]

Another explanation is production of bone – forming factors like transforming growth factor- β or bone morphogenetic proteins by tumor cells, causing metaplastic transformation of the undifferentiated mesenchymal stromal stem cells into osteoblasts. [29]

Other authors have suggested that osseous metaplasia seems to be an uncommon reaction to tissue aggression in an attempt at repair.

No prognostic significance has been attributed to this unusual phenomenon.

DISCLOSURE OF INTEREST

All authors declare any financial interest with respect to this manuscript.

CONCLUSION

Ossification seen in an ovarian fibroma is an unusual feature; its pathogenic mechanisms and the probability of clinical implications remain to be clarified.

Multidisciplinary approach is mandatory in order to establish accurate an assiduous management.

REFERENCES

- [1] Dolan, M.S., C. Hill, and F.A. Valea, *Benign Gynecologic Lesions*, in *Comprehensive Gynecology*, R.A. Lobo, et al., Editors. 2016, Elsevier Health Sciences.
- [2] Landim, F.M., et al., *Vaginal osseous metaplasia*. Arch Gynecol Obstet, 2009. **279**(3): p. 381-4. <https://doi.org/10.1007/s00404-008-0706-4>
- [3] Miliaras, D., M. Ketikidou, and S. Pervana, *Osseous metaplasia in ovarian tumours: a case with serous cystadenoma*. J Clin Pathol, 2007. **60**(5): p. 582-3.
- [4] Misseevich, I. and J.H. Boss, *Metaplastic bone in a mucinous cystadenoma of the ovary*. Pathol Res Pract, 2000. **196**(12): p. 847-8. [https://doi.org/10.1016/s0344-0338\(00\)80086-2](https://doi.org/10.1016/s0344-0338(00)80086-2)
- [5] Shipton, E.A. and S.D. Meares, *Heterotopic Bone Formation in the Ovary*. Aust N Z J Obstet Gynaecol, 1965. **5**(2): p. 100-2. <https://doi.org/10.1111/j.1479-828x.1965.tb00298.x>
- [6] Zahn, C.M. and B.S. Kendall, *Heterotopic bone in the ovary associated with a mucinous cystadenoma*. Mil Med, 2001. **166**(10): p. 915-7. <https://doi.org/10.1093/milmed/166.10.915>
- [7] Barua, R. and L.W. Cox, *Occurrence of bone in serous cystadenocarcinoma of the ovary*. Aust N Z J Obstet Gynaecol, 1982. **22**(3): p. 183-6. <https://doi.org/10.1111/j.1479-828x.1982.tb01440.x>
- [8] Bosscher, J., et al., *Osseous metaplasia in ovarian papillary serous cystadenocarcinoma*. Gynecol Oncol, 1990. **39**(2): p. 228-31. [https://doi.org/10.1016/0090-8258\(90\)90439-r](https://doi.org/10.1016/0090-8258(90)90439-r)
- [9] Mukonoweshuro, P. and A. Oriowolo, *Stromal osseous metaplasia in a low-grade ovarian adenocarcinoma*. Gynecol Oncol, 2005. **99**(1): p. 222-4. <https://doi.org/10.1016/j.ygyno.2005.05.040>
- [10] Gabrilovich, S., et al., *Ovarian Endometrioma with Osseous Metaplasia: A Case Report and Review of the Literature*. Journal of Gynecologic Surgery, 2019. **35**(4): p. 246-252. <https://doi.org/10.1089/gyn.2019.0007>
- [11] Mooney, E.E., K.P. Vaidya, and F.A. Tavassoli, *Ossifying well-differentiated Sertoli-Leydig cell tumor of the ovary*. Ann Diagn Pathol, 2000. **4**(1): p. 34-8. [https://doi.org/10.1016/s1092-9134\(00\)90008-x](https://doi.org/10.1016/s1092-9134(00)90008-x)
- [12] Godbole, P., A. Outram, and N. Sebire, *Osseous metaplasia in a benign ovarian cyst in association with cloacal anomaly*. J Clin Pathol, 2005. **58**(3): p. 334-5.
- [13] Badawy, S.Z., et al., *Supernumerary ovary with an endometrioma and osseous metaplasia: a case report*. Am J Obstet Gynecol, 1995. **173**(5): p. 1623-4. [https://doi.org/10.1016/0002-9378\(95\)90661-4](https://doi.org/10.1016/0002-9378(95)90661-4)

- [14] Rosa e Silva, J.C., et al., *Isolated osseous ovarian metaplasia: case report*. Eur J Gynaecol Oncol, 2010. **31**(4): p. 469-70.
- [15] Morizane, M., et al., *Ossifying luteinized thecoma of the ovary*. Arch Gynecol Obstet, 2003. **267**(3): p. 167-9. <https://doi.org/10.1007/s00404-001-0282-3>
- [16] Pervatkar, S.K., R. Rao, and U.S. Dinesh, *Ossifying luteinized thecoma of the ovary with endometrial adenocarcinoma*. Indian J Pathol Microbiol, 2009. **52**(2): p. 222-4. <https://doi.org/10.4103/0377-4929.48925>
- [17] Young, R.H., P.B. Clement, and R.E. Scully, *Calcified thecomas in young women. A report of four cases*. Int J Gynecol Pathol, 1988. **7**(4): p. 343-50. <https://doi.org/10.1097/00004347-198812000-00005>
- [18] Cochrane, J.B., *A case of calcified ovarian fibroma in a young adolescent*. J Obstet Gynaecol Br Emp, 1950. **57**(5): p. 801-2.
- [19] Lu, J.C., *[Complete calcification of ovarian fibroma: a case report]*. Zhonghua Fang She Xue Za Zhi, 1960. **8**: p. 59.
- [20] Terada, S., et al., *Parovarian fibroma with heterotopic bone formation of probable wolffian origin*. Gynecol Oncol, 1993. **50**(1): p. 115-8. <https://doi.org/10.1006/gyno.1993.1174>
- [21] Chen, C.P., et al., *Bilateral calcified ovarian fibromas in a patient with Sotos syndrome*. Fertil Steril, 2002. **77**(6): p. 1285-7. [https://doi.org/10.1016/s0015-0282\(02\)03118-7](https://doi.org/10.1016/s0015-0282(02)03118-7)
- [22] Akbulut, M., et al., *A probable secondary infertility due to osseous metaplasia of the endometrium*. Arch Gynecol Obstet, 2008. **277**(6): p. 563-5. <https://doi.org/10.1007/s00404-007-0515-1>
- [23] Bahçeci, M. and L.C. Demirel, *Osseous metaplasia of the endometrium: a rare cause of infertility and its hysteroscopic management*. Hum Reprod, 1996. **11**(11): p. 2537-9.
- [24] Lainas, T., et al., *Osseous metaplasia: case report and review*. Fertil Steril, 2004. **82**(5): p. 1433-5. <https://doi.org/10.1016/j.fertnstert.2004.04.055>
- [25] Manzur, Y.A. and C.S. Varela, *[Bony metaplasia of the endometrium. Report of two cases]*. Rev Med Chil, 2010. **138**(8): p. 1004-7.
- [26] Bhatia, N.N. and M.G. Hoshiko, *Uterine osseous metaplasia*. Obstet Gynecol, 1982. **60**(2): p. 256-9.
- [27] Polat, I., et al., *Osseous metaplasia of the cervix and endometrium: a case of secondary infertility*. Fertil Steril, 2011. **95**(7): p. 2434.e1-4. <https://doi.org/10.1016/j.fertnstert.2011.02.001>
- [28] Campo, S., et al., *Simultaneous ovarian and endometrial osseous metaplasia: a case report*. J Reprod Med, 2007. **52**(3): p. 241-2.
- [29] Kumar, R., et al., *An Unusual Case of Extensive Osseous Metaplasia in Fibroma of Ovary*. Int J Surg Pathol, 2018. **26**(8): p. 733-734. <https://doi.org/10.1177/1066896918766239>

Received on 24-07-2020

Accepted on 01-08-2020

Published on 15-08-2020

<https://doi.org/10.31907/2309-4400.2020.08.09>

© 2020 Vasileiadou Dimitra et al; Licensee Green Publishers. This is an open access article licensed under the terms of the Creative Commons Attribution Non-Commercial License (<http://creativecommons.org/licenses/bync/3.0/>) which permits unrestricted, non-commercial use, distribution and reproduction in any medium, provided the work is properly cited.