

# Obstetric Outcomes of Position Abnormalities Detected by Intrapartum Suprapubic Transabdominal Ultrasound

Edgar Allan Villagómez Mendoza\*, Jaime Edgar Martínez Niño and Aldo Toriz Prado

General Hospital of Ecatepec Dr. José María Rodríguez, State of Mexico

**Abstract:** *Objective:* to propose the use of ultrasound during abnormal labor, as a detection of position abnormalities, to evaluate the way of resolution of pregnancy and reduce maternal-fetal complications.

*Materials and Methods:* Prospective, cross-sectional, descriptive study, carried out in term pregnant patients, carried out in a second level of care in December 2018 to July 2019, the population was divided into group 1 (it included 15 patients with evolution abnormal labor in which no ultrasound was performed to detect position abnormalities) and group 2 (15 patients with abnormal evolution of labor and ultrasound detection of position anomaly were included) to determine the usefulness of diagnosis by ultrasound and its association with maternal-fetal morbidity and mortality.

*Results:* A total of 30 patients were registered, both groups with 15 patients each, in group 1, 11 patients with maternal and fetal morbidity were reported, whose resolution was vaginal in which position abnormalities were detected during the obstetric event, In group 2, 15 patients were reported with abnormal evolution of labor and with a diagnosis of position abnormalities, detected by ultrasound during the second period of labor, whose resolution of pregnancy was abdominal, without complications, in 4 Patients the indication was due to fetal compromise.

*Conclusions:* Timely detection in the second period of labor for position abnormalities is an effective method to reduce maternal-fetal complications.

**Keywords:** Abnormal fetal position, dysfunctional labor, second period of prolonged labor.

## INTRODUCTION

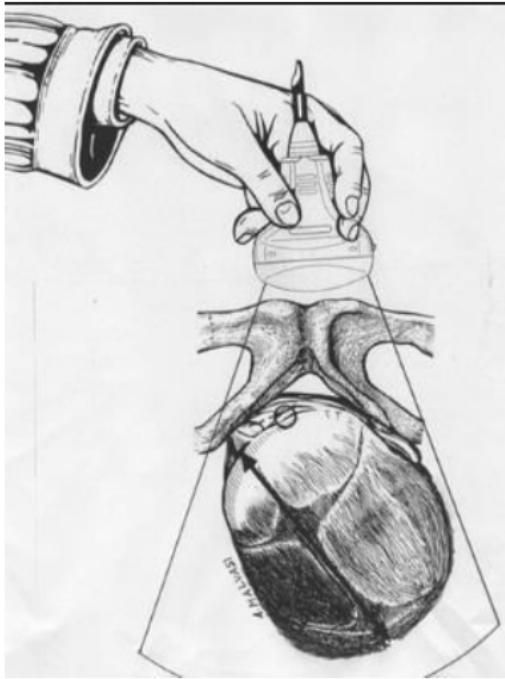
It is currently demonstrated that evidence in vaginal examination does not provide an accurate evaluation of the position and fetal descent, therefore, the use of intrapartum ultrasound plays an important role and can be crucial in determining the route of birth, as this can help to the prediction of a cesarean delivery in a timely manner avoiding maternal-fetal complications, position abnormalities are recognized causes of lack of evolution of labor, has an incidence of 10% of cases, therefore, the usefulness of performing Intrapartum ultrasound is attractive as a complementary study [1]. Akmal *et al.*, reported that the routine digital examination cannot identify the correct fetal position since it is a dependent operator and whether or not caput succedaneum [2] is present, therefore, the literature reported that during the First period of labor up to 60% is not able to know the position of the cephalic pole through exploration n digital and 30% in the second period of labor, therefore, ultrasound during labor, is more accurate than digital vaginal examination particularly in cases where there is poor descent of the head pole, molding or succeeded caput, which corresponds to its use being useful for the prediction, diagnosis and optimization of the delivery resolution route in a timely manner to reduce catastrophic maternal fetal outcomes [3].

A great diversity of ultrasound signs have been published to predict the evolution of labor and to diagnose abnormal labor due to positional abnormalities. When the positional anomaly is occipito-posterior after the transabdominal exploration, we can find the fetal orbits facing upwards. the flexion is inferred by the profile view of the face that shows the chin resting on the chest, the choroid plexuses diverge later, in the sagittal examination the third ventricle can be seen, in the variety of transverse occipito position, the fetal spine a Often found lateral, the fetal orbits are directed laterally, however, this publication focuses on the ease of reproduction of the strabismus sign which we can explore through the transabdominal route, orienting the transducer transversely, above the pubic symphysis, in the variety of occipito-posterior position we can observe the fetal orbits oriented upwards and flexion of the chin towards the fetal chest, in the occipito-transverse position the fetal cerebral midline is observed in a transverse section, and the sign of strabismus can be demonstrated by finding only a fetal orbit laterally, therefore, the literature Consider the sign of strabismus as pathognomonic of fetal malposition [4-6] Figures 1 and 2.

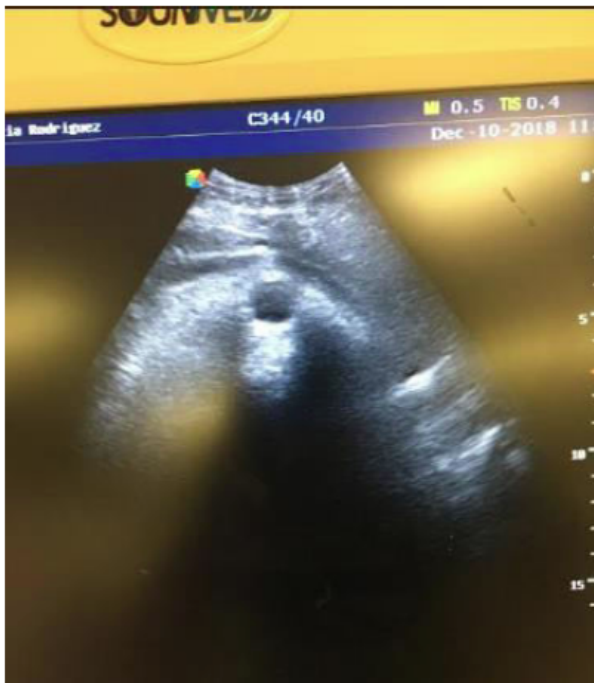
## MATERIALS AND METHODS

Prospective, cross-sectional, descriptive study, carried out in term pregnant patients, carried out in a second level of care in December 2018 to July 2019, the population was divided into group 1 (15 patients

\*Address correspondence to this author at the Edgar Allan Villagómez Mendoza, Lake Nyasa 46 Col. Jardines de Morelos, Ecatepec, CP 55070, State of Mexico; Tel: 5539547359; E-mail: allan.villagomez.m@gmail.com



**Figure 1:** Suprapubic transabdominal ultrasound.



**Figure 2:** Sign of strabismus in occipito-transverse.

with abnormal evolution of labor were included in those who did not perform intrapartum suprapubic transabdominal ultrasound for detection of position abnormalities) and group 2 (15 patients with abnormal evolution of labor and suprapubic transabdominal ultrasound of position anomaly were included) to determine the usefulness of the anomaly diagnosis of

position by ultrasound and its association with maternal-fetal morbidity and mortality, the inclusion criteria: patients with term pregnancy in labor, exclusion criteria: patients with preterm pregnancies, term with 2 or more C-sections, with termination of pregnancy via Caesarean section by fetal or maternal indication, elimination criteria: patient it is with alteration in the placental insertion, intergenic period less than 18 months.

For its analysis, measures of central tendency and dispersion were used, the average of the standard deviation and frequencies were calculated as appropriate, the comparison of means was made with the ANOVA test, the value of  $p < 0.05$  was considered statistically significant. the SPSS program version 24 for Windows.

## RESULTS

A total of 30 patients were registered, the population was divided into 2 groups, both groups with 15 patients each, in group 1 11 (36%) patients with maternal and fetal morbidity were reported, whose resolution was vaginal in which position abnormality was observed during the obstetric event, of which 3 (10%) patients with third-degree perineal tear, 3 (10%) patients with low recovered recovery, 1 (3%) perinatal death, 4 (13%) obstetric hemorrhages with a mean bleeding of 825cc and 4 (13%) births without complications, in group 2, 11 (36%) patients with abnormal evolution of labor were reported in which position abnormality was diagnosed by transabdominal ultrasound suprapubic during the second period of labor, whose resolution of pregnancy was abdominal, in 4 (13%) of them the indication was due to fetal compromise, no complications associated with significant position abnormalities were reported Statistical location of  $p < 0.037$ . Tables 1 and 2. The ACOG criteria were used for the second period of labor, suprapubic transabdominal ultrasound was performed only in patients with abnormal labor, in relation to the ANOVA test there was greater maternal and fetal morbidity when the Resolution of this was vaginal and association of position anomaly, higher incidence in pelvic floor lesions and notable increase in blood loss, the incidence of complications when associated with position abnormality not previously detected until the obstetric event was 36% , according to the objective of the study when performing ultrasound during the second period of labor in patients with abnormal progression, prevents associated future complications Tables 3 and 4.

Table 1: Group 1 Obstetric and Perinatal Outcomes

Patients	Gestations	Resolution of pregnancy	Maternal and fetal complications	Position anomaly detected in the obstetric event	Position anomaly detected by ultrasound
1	1	Vaginal delivery	Grade 3A perineal tear	Yes	No
2	1	Vaginal delivery	Grade 3A perineal tear	Yes	No
3	2 C1	Vaginal delivery	Grade 3A perineal tear	Yes	No
4	1	Vaginal delivery	Apgar under recovered	Yes	No
5	2 C1	Vaginal delivery	Apgar under recovered	Yes	No
6	3 P1 C1	Vaginal delivery	700cc obstetric hemorrhage	Yes	No
7	1	Vaginal delivery	Apgar under recovered	Yes	No
8	2 P1	Vaginal delivery	800cc obstetric hemorrhage	Yes	No
9	2 C1	Vaginal delivery	700cc obstetric hemorrhage	Yes	No
10	1	Vaginal delivery	Perinatal death	Yes	No
11	2 C1	Vaginal delivery	1100cc obstetric hemorrhage	Yes	No
12	1	Vaginal delivery	None	No	No
13	3 P2	Vaginal delivery	None	No	No
14	2 P1	Vaginal delivery	None	No	No
15	3 P2	Vaginal delivery	None	No	No

Table 2: Group 2 Obstetric and Perinatal Outcomes

patients	Gestations	Resolution of pregnancy	Maternal and fetal complications	Position anomaly detected in the obstetric event	Position anomaly detected by ultrasound
1	1	Caesarean section	None	yes	yes
2	2 C1	Caesarean section	None	yes	yes
3	2 A1	Caesarean section	None	yes	Yes
4	1	Caesarean section	None	Yes	yes
5	2 P1	Caesarean section	None	yes	Yes
6	1	Caesarean section	None	Yes	yes
7	1	Caesarean section	None	yes	Yes
8	2 P1	Caesarean section	None	Yes	yes
9	1	Caesarean section	None	yes	Yes
10	2 C1	Caesarean section	None	Yes	yes
11	1	Caesarean section	None	yes	Yes
12	2 C1	Caesarean section	Loss of fetal well-being	No	No
13	3 P3	Caesarean section	Loss of fetal well-being	No	no
14	1	Caesarean section	Loss of fetal well-being	No	No
15	2 P1	Caesarean section	Premature detachment of placenta normoinserta	No	No

**Table 3: Group 1 Maternal and Fetal Complications**

	Frequency	Percentage
perineal tear	3	20,0
obstetric hemorrhage	4	26,7
apgar low recovered	3	20,0
Perinatal death	1	6,7
without complications	4	26,7
Total	15	100,0

**Table 4: Group 2 Maternal and Fetal Complications**

	Frequency	Percentage
without complications	11	73,3
Loss of fetal well-being	3	20,0
Premature detachment of placenta normoinserta	1	6,7
Total	15	100,0

## DISCUSSION

Intrapartum ultrasound allows easy and rapid detection of fetal malposition during the second period of work, according to the recommendations of the American College of Obstetricians and Gynecologists (ACOG) the time allowed is 2 hours for nulliparous women and 3 hours with epidural anesthesia and 1 hour for multiparous women and 2 hours with epidural anesthesia, Senecal *et al.*, compared the duration between the various position abnormalities, that is, occipito-anterior 3.1 hours, occipito-posterior 3.8 hours and occipito-transverse 3.6 hours, recently a trial Randomized control showed that adding an hour to the ACOG criteria decreased the incidence of caesarean sections, showed no significant maternal-fetal morbidity with the control group [7,8], this could not be corroborated in our study since they did not reach the extra hour suggested by the study, due to the presence of loss of fetal well-being, so our study adhered to the criteria of ACOG, Fetal position abnormalities in the second period of labor increases the risk of caesarean section and with it the risk of obstetric hemorrhage greater than 500ml, hysterotomy prolongation during the caesarean section that compromised the uterine vessels, instrumented delivery, increased the use of oxytocin, wide episiotomy, third and fourth degree perineal tears and neonatal complications (neonatal asphyxiation, lowering at 5 minutes, perinatal death) therefore the interest of using intrapartum ultrasound

only in patients with abnormal work progress of childbirth, in this study it was observed that the second period of prolonged labor, is associated with an increase in obstetric hemorrhage, perineal tears and worsens the neonatal outcome, there are multiple ultrasound signs to determine fetal malposition, however, some of them with greater complexity, in our study the sign of strabismus as pathognomonic anomaly is reported occipito-transverse and occipito-posterior position the latter more frequent in 10-30% of cases, since during the second period of labor 80% of these rotates spontaneously, therefore, before an abnormal, poor progression decrease of the head pole, increase in the duration of the second period of labor, the use of ultrasound is justified, to reduce maternal-fetal complications, especially in this period where uterine perfusion and fetal oxygenation are compromised, in our The study showed 4 cases of neonatal involvement, one of them with perinatal death, so its use is fully recommended, the limitations of the study are not having the ultrasound equipment in the toco-surgical unit, personnel trained for its execution, is dependent and important operator only perform in abnormal labor, that is, do not perform it routinely since it can increase in a way exponential the rate of caesarean sections and with this greater long-term complications [9-11]. In conclusion it is essential to know the different varieties of position, height of presentation and recognize when it is an abnormal labor, the clinical diagnosis by vaginal examination can

be particularly difficult and it is subjective in most cases, the timely detection of the sign of Strabismus (present in a variety of persistent occipito-posterior and transverse position) detected by suprapubic transabdominal ultrasound is very reproducible, pathognomonic and useful for the gynecologist-obstetrician in the management of abnormal labor in which the resolution of pregnancy is necessary by Instrumented or abdominal delivery in a timely manner, which has an impact on the reduction of maternal and fetal complications.

## REFERENCES

- [1] Molina, *et al.* Ultrasound in labor and delivery. *Fetal Diagn Ther* 2010; 27(2): 61-7.  
<https://doi.org/10.1159/000287588>
- [2] Akmal S, *et al.* Intrapartum sonography to determine fetal head position. *J Matern Fetal Neonatal Med* 2002; 12(3): 172-7.  
<https://doi.org/10.1080/jmf.12.3.172.177>
- [3] Souka A, *et al.* Intrapartum ultrasound for the examination of the fetal head position in normal and obstructed labor. *J Matern Fetal Neonatal Med* 2003; 13(1): 59-63.  
<https://doi.org/10.1080/jmf.13.1.59.63>
- [4] Bellusi F, *et al.* The use of intrapartum ultrasound to diagnose malpositions and cephalic malpresentations. *Am J Obstet Gynecol* 2017; 217(6): 633-641.  
<https://doi.org/10.1016/j.ajog.2017.07.025>
- [5] Villagomez E, *et al.* Detección de anomalías de posición mediante ultrasonido transabdominal suprapúbico. Reporte de dos casos. *Ginecol Obstet Mex* 2019; 87(8): 549-554.
- [6] Fouche J, Simon E. Ultrasound in monitoring of the second stage of labour, *Gynecologie Obstetrique & Fertilité* 2012; 40: 658-665.  
<https://doi.org/10.1016/j.gyobfe.2012.09.001>
- [7] Gimovsky A, Berghella V. Randomized controlled trial of prolonged second extending the time limit vs usual guidelines. *American Journal of Obstetrics and Gynecology* March 2016.  
<https://doi.org/10.1016/j.ajog.2015.10.139>
- [8] FIGO Safe motherhood and newborn health (SMNH) Committee, Management of second stage of labor. *International Journal of Gynecology and Obstetrics* 2012; 119: 111-116.  
<https://doi.org/10.1016/j.ijgo.2012.08.002>
- [9] Senecal J, Xiong X. Effect of Fetal Position on Second-Stage Duration and Labor Outcome, *The American College of Obstetricians and Gynecologists* 2005; 105(4).  
<https://doi.org/10.1097/01.AOG.0000154889.47063.84>
- [10] Ghi T, Maroni E. Sonographic pattern of fetal head descent: relationship with duration of active second stage of labor and occiput position at delivery, *Ultrasound Obstet Gynecol* 2014; 44: 82-89.  
<https://doi.org/10.1002/uog.13324>
- [11] Martino V, Iliceto N. Occipito-posterior fetal head position, maternal and neonatal outcome, *Minerva Ginecol* 2007; 59(4): 459-64.

Received on 20-11-2019

Accepted on 05-12-2019

Published on 23-12-2019

DOI: <https://doi.org/10.31907/2309-4400.2019.07.02>

© 2019 Mendoza *et al.*; Licensee Green Publishers.

This is an open access article licensed under the terms of the Creative Commons Attribution Non-Commercial License (<http://creativecommons.org/licenses/by-nc/3.0/>) which permits unrestricted, non-commercial use, distribution and reproduction in any medium, provided the work is properly cited.